

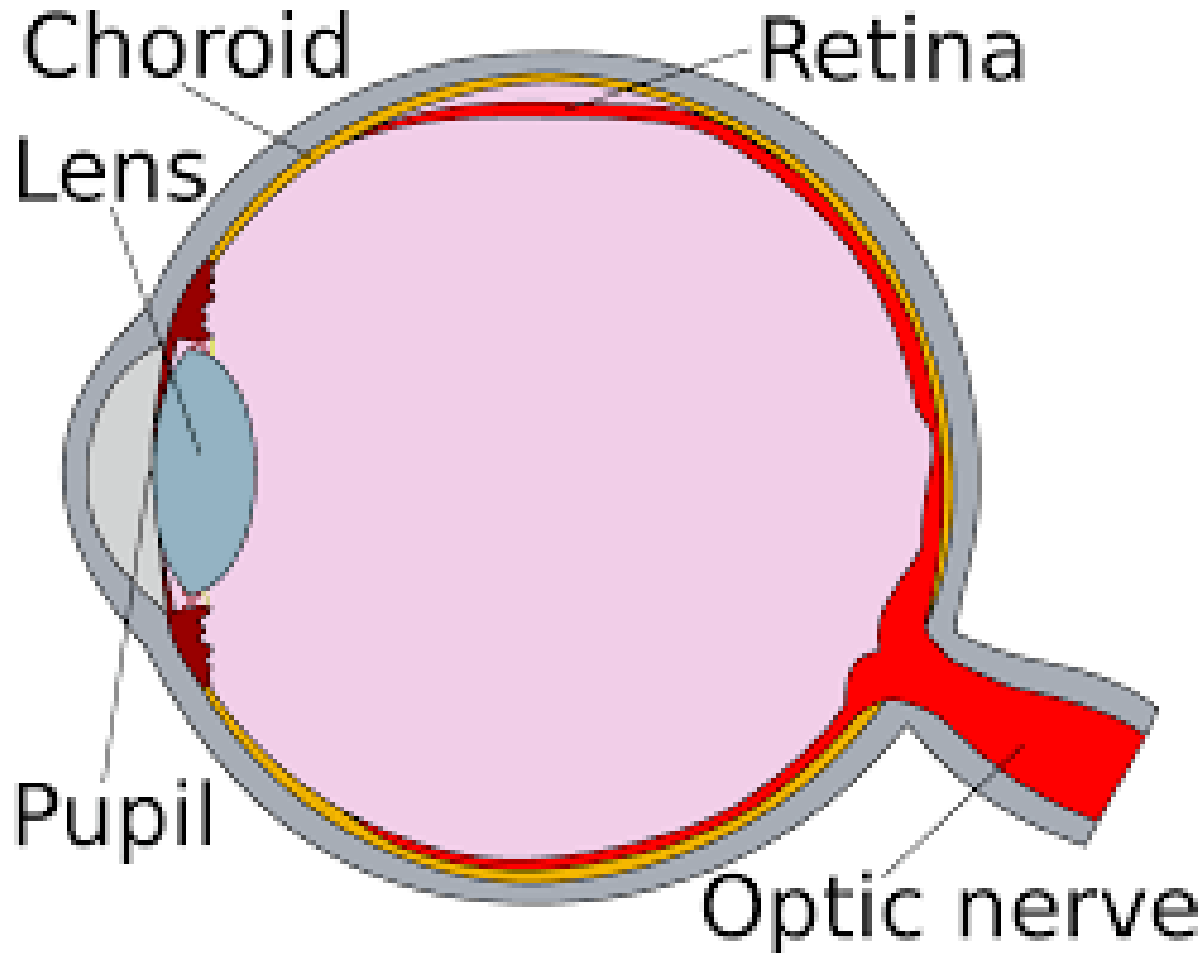
Why Grandma Can't See
Or
Common Vision Problems of the Elderly
And
What Can Be Done to Prevent Them



Grandma

Why Grandma Can't See

- First a word about seeing



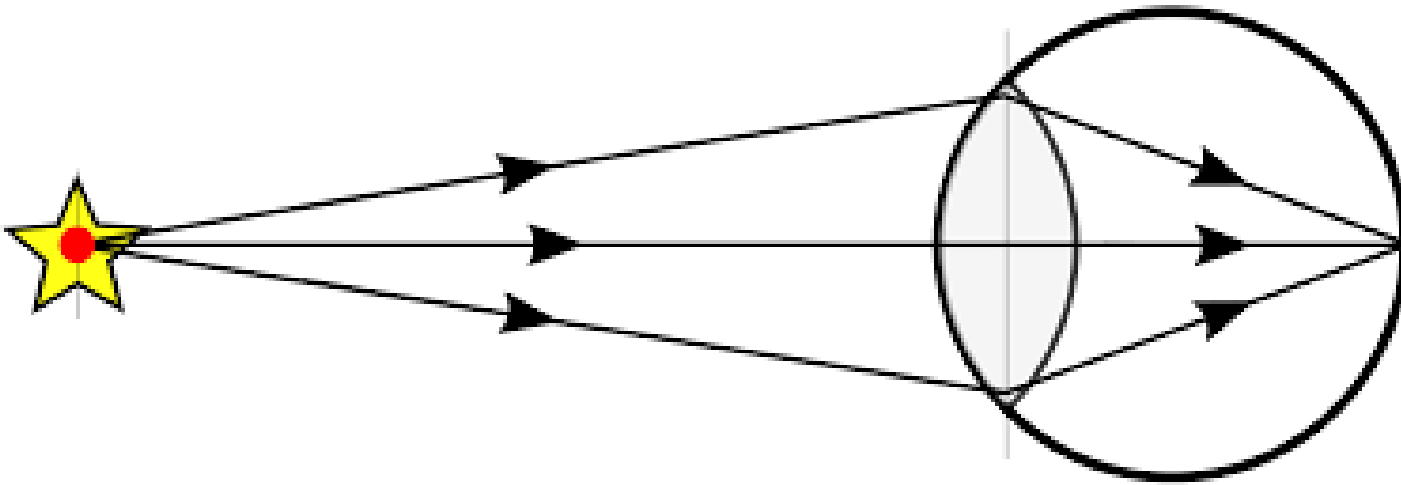
Grandma

Why Grandma Can't See

- First a word about seeing



Grandma

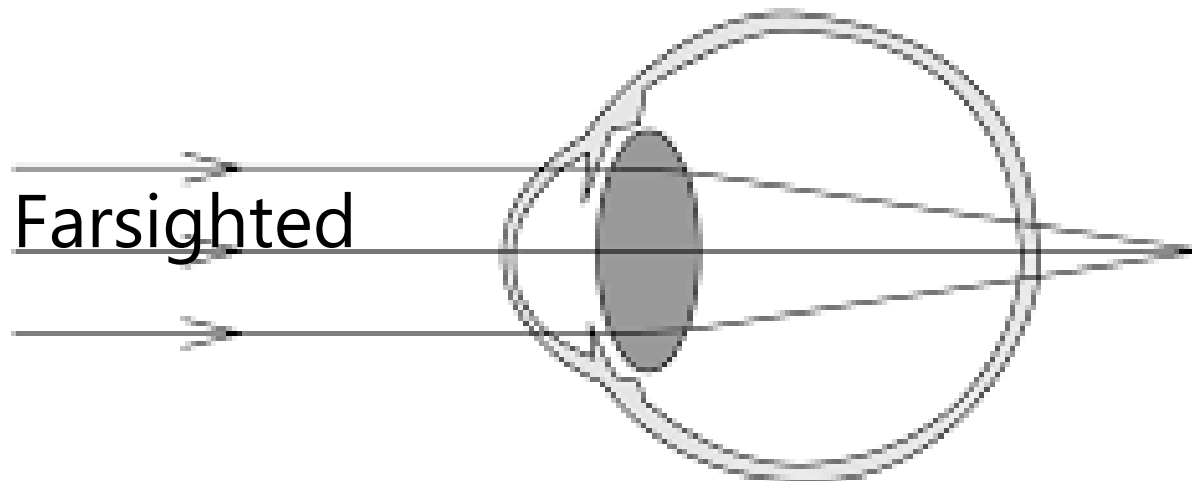
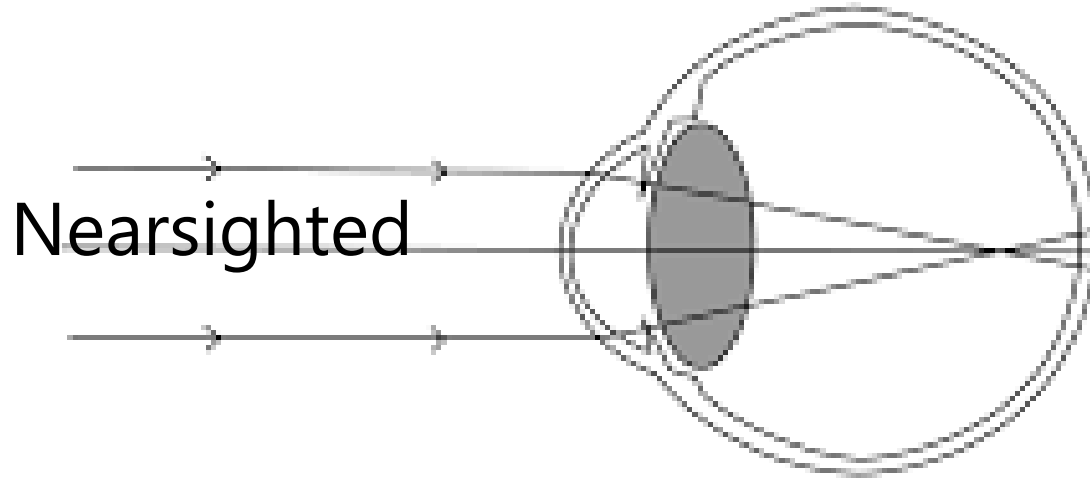


Why Grandma Can't See

- First a word about seeing



Grandma

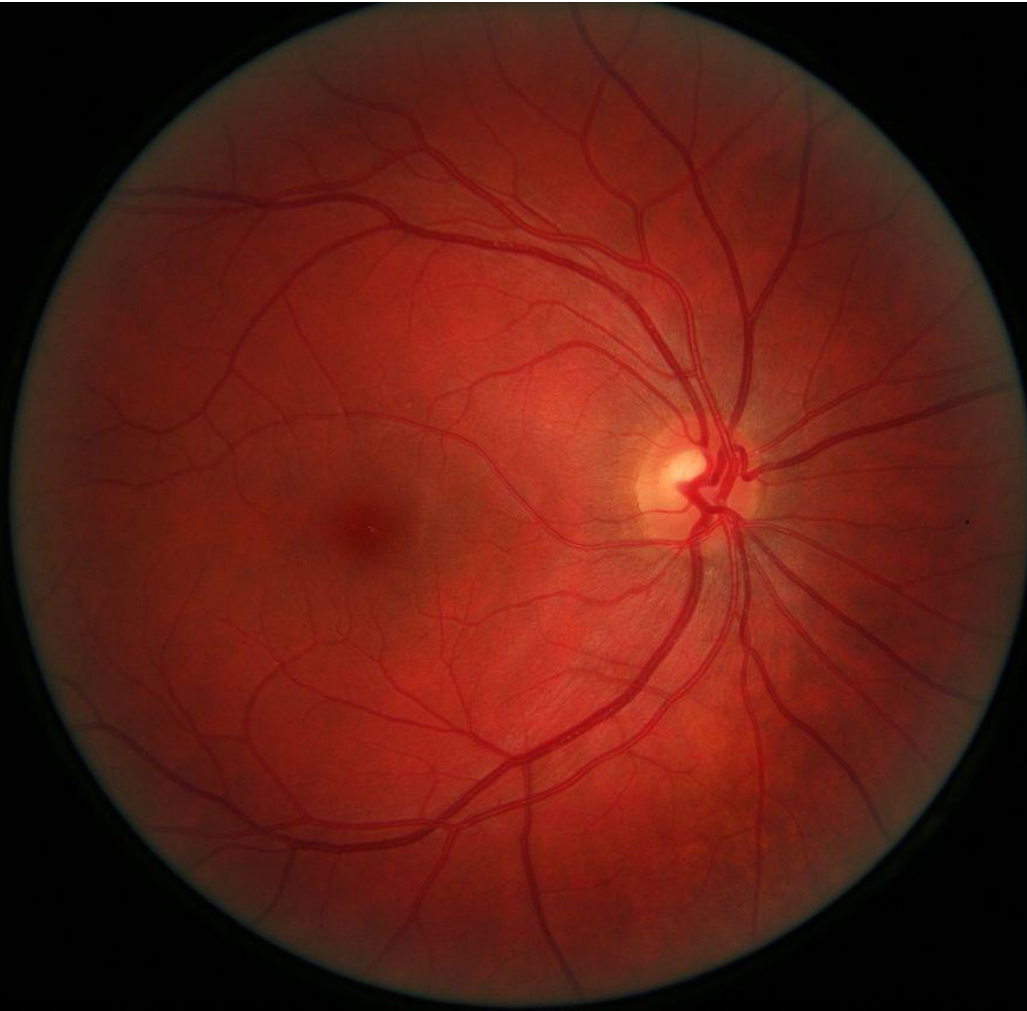


Why Grandma Can't See

Basic Ideas About Eye Disease



Grandma

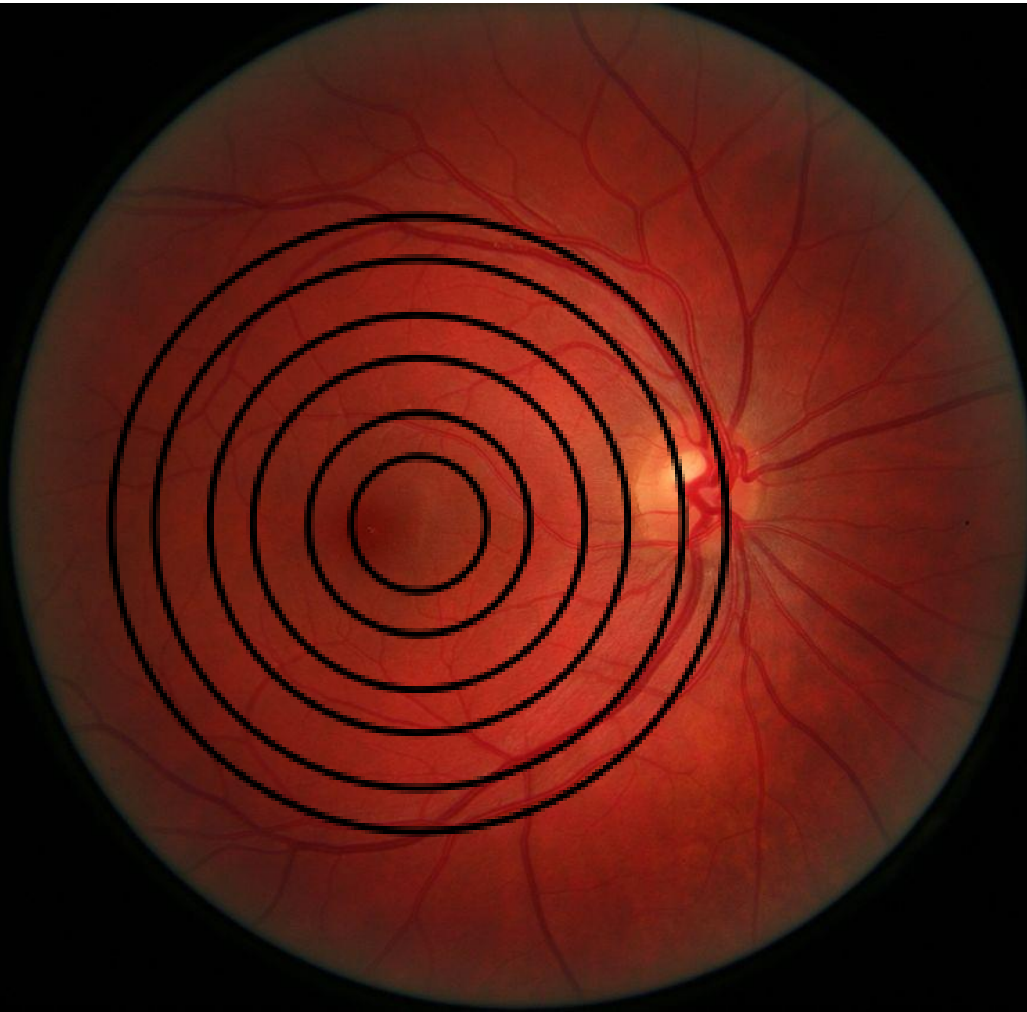


Why Grandma Can't See

Basic Ideas About Eye Disease



Grandma

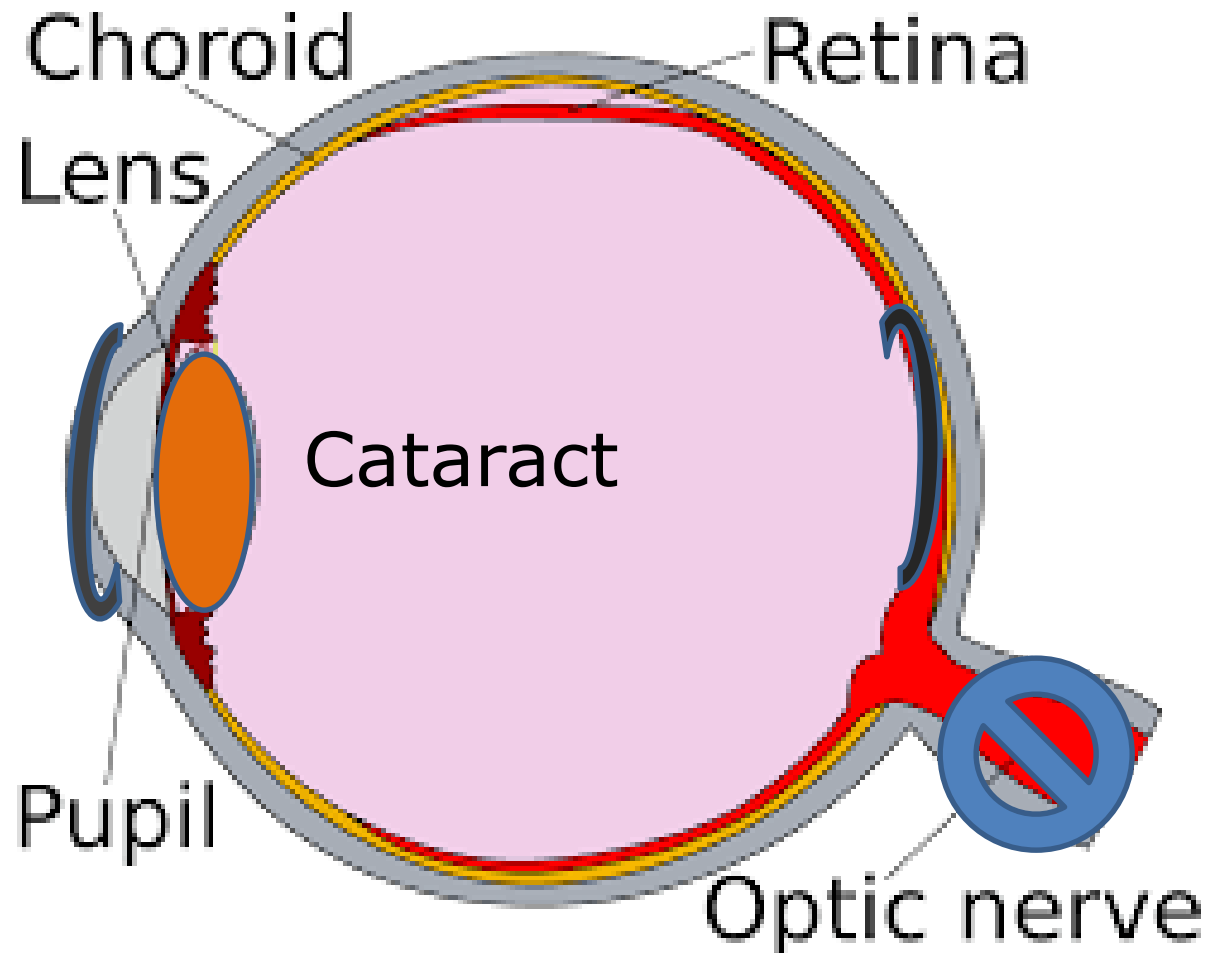


Why Grandma Can't See

Basic Ideas About Eye Disease



Grandma



Why Grandma Can't See

Why My Grandma Couldn't See
Histoplasmosis

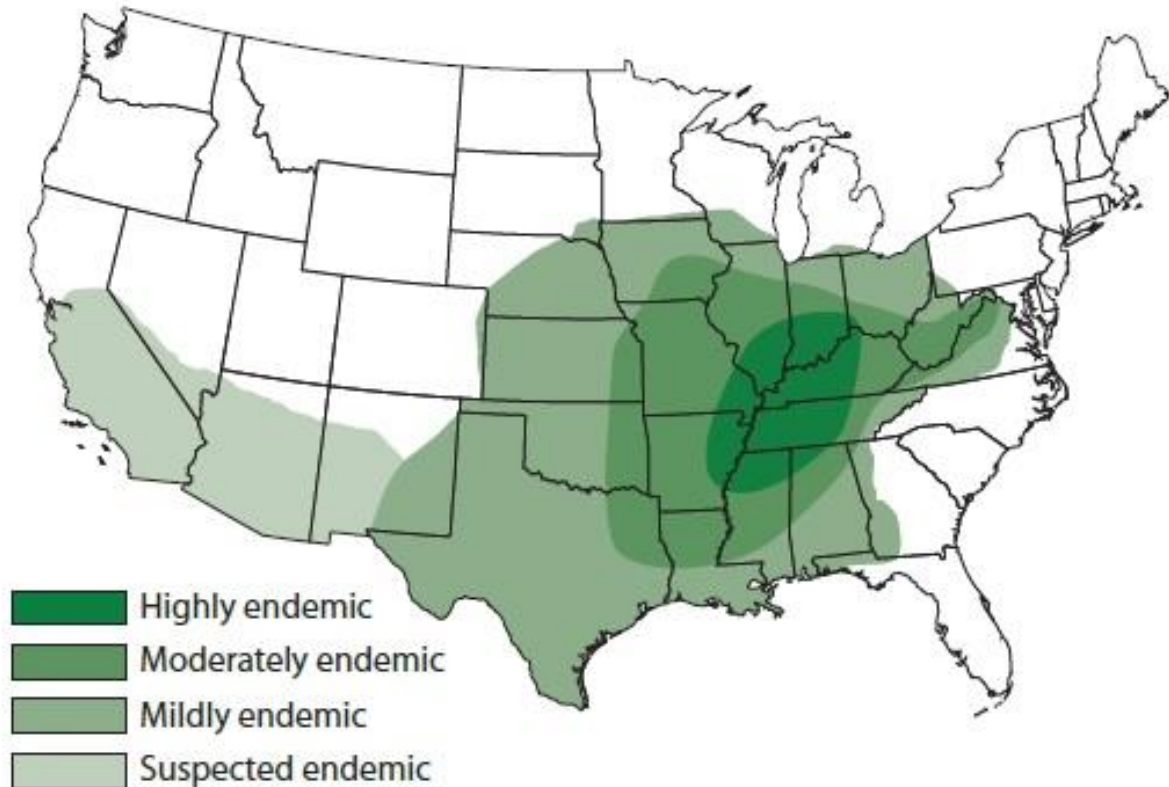
Histoplasma capsulatum-

• Fungus only able to grow in the Ohio River/Upper
Mississippi River Basins



Grandma

Areas Endemic for Histoplasmosis



Why Grandma Can't See

Why My Grandma Couldn't See
Histoplasmosis

Histoplasma capsulatum-

- *Fungus only able to grow in the Ohio River/Upper Mississippi River Basins*
- *Birds are the primary carrier.*



Grandma



Why Grandma Can't See

Why My Grandma Couldn't See
Histoplasmosis

Histoplasma capsulatum-

- *Fungus only able to grow in the Ohio River/Upper Mississippi River Basins*
- *Birds are the primary carrier.*
- *Transmitted to humans from bird feces and contaminated soil, unwashed fruits and vegetables.*



Grandma



Why Grandma Can't See

Why My Grandma Couldn't See
Histoplasmosis

Histoplasma capsulatum-

- *Fungus only able to grow in the Ohio River/Upper Mississippi River Basins*
- *Birds are the primary carrier.*
- *Transmitted to humans from bird feces and contaminated soil, unwashed fruits and vegetables.*
 - *Inhaled by humans*
 - *The primary infection is the lungs*
 - *Spores from the lungs travel to the eyes via the circulatory system*
 - *The spores lodge in the tiny capillaries in the choroid*



Grandma

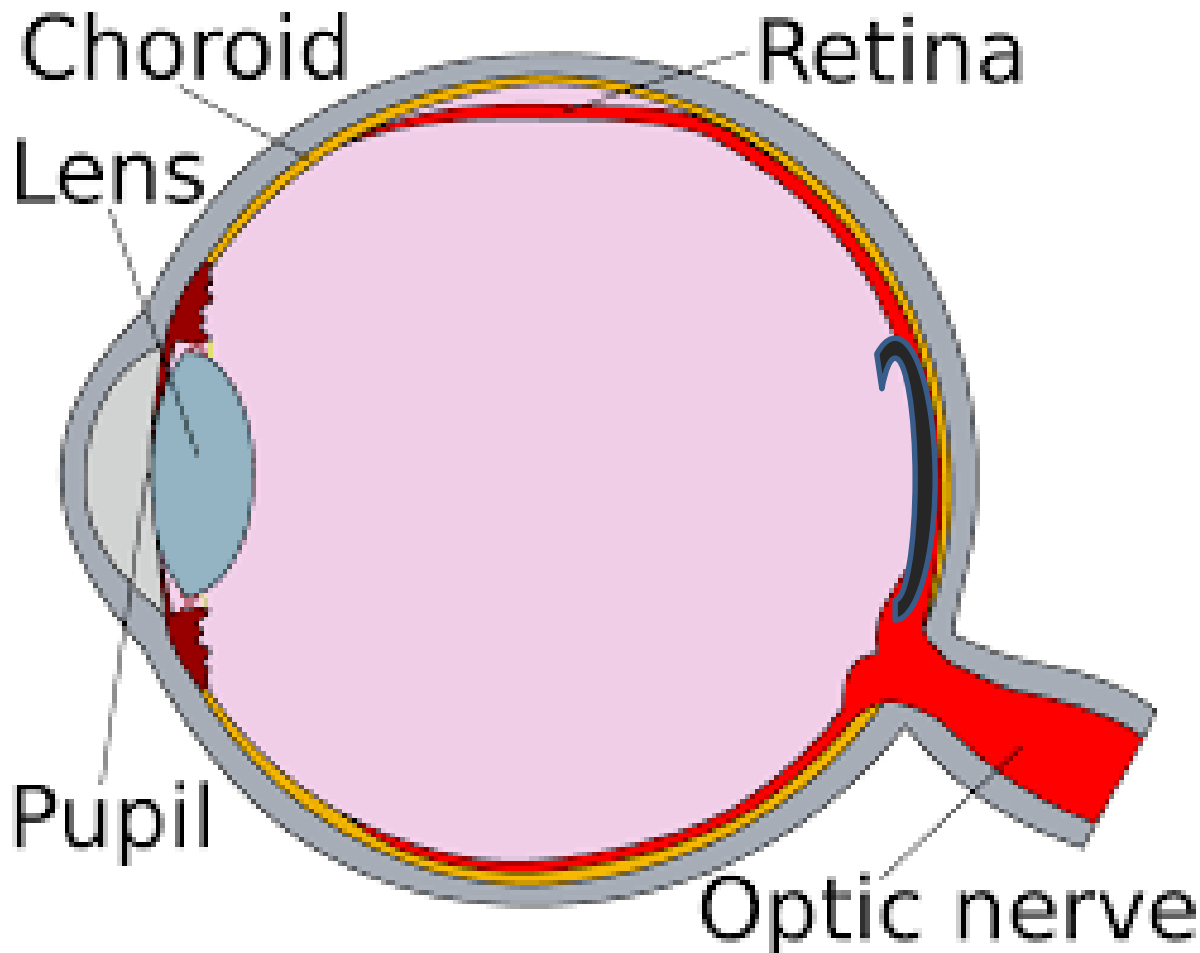
Why Grandma Can't See

Why My Grandma Couldn't See
Histoplasmosis

Histoplasma capsulatum



Grandma



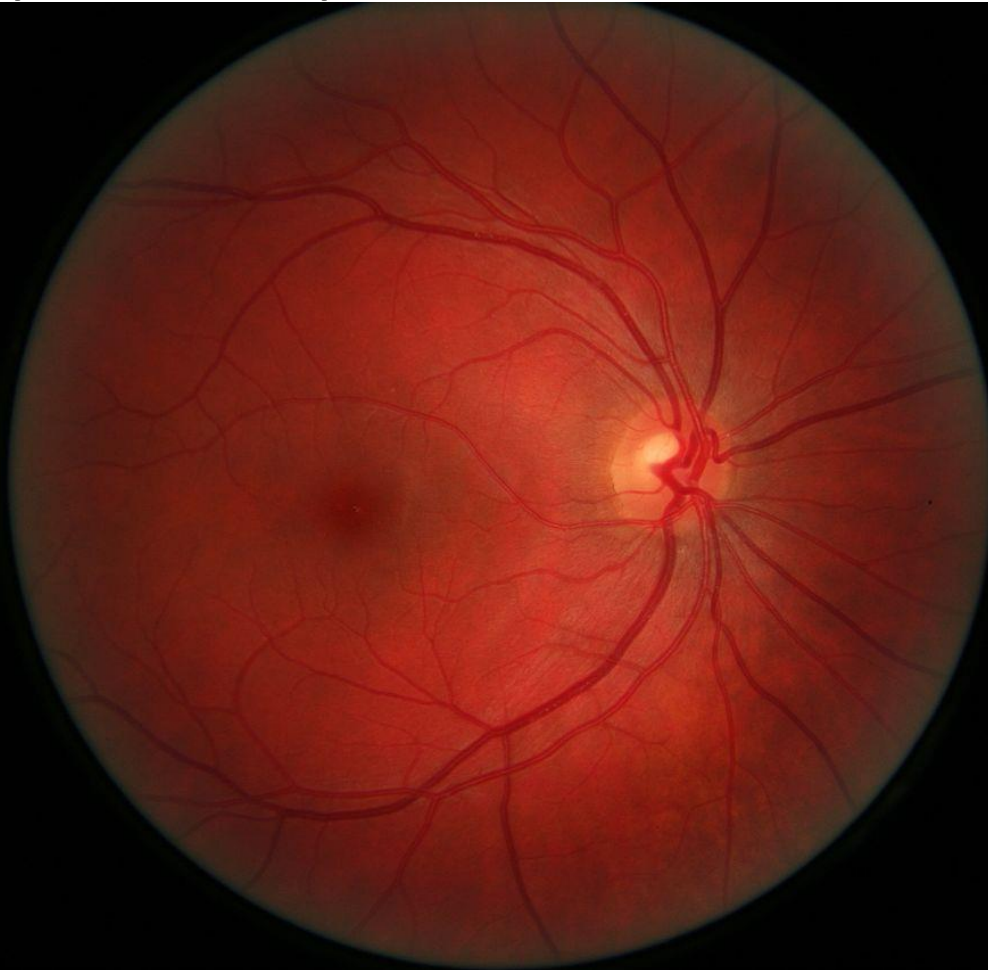
Why Grandma Can't See

Why My Grandma Couldn't See
Histoplasmosis

Histoplasma capsulatum



Grandma



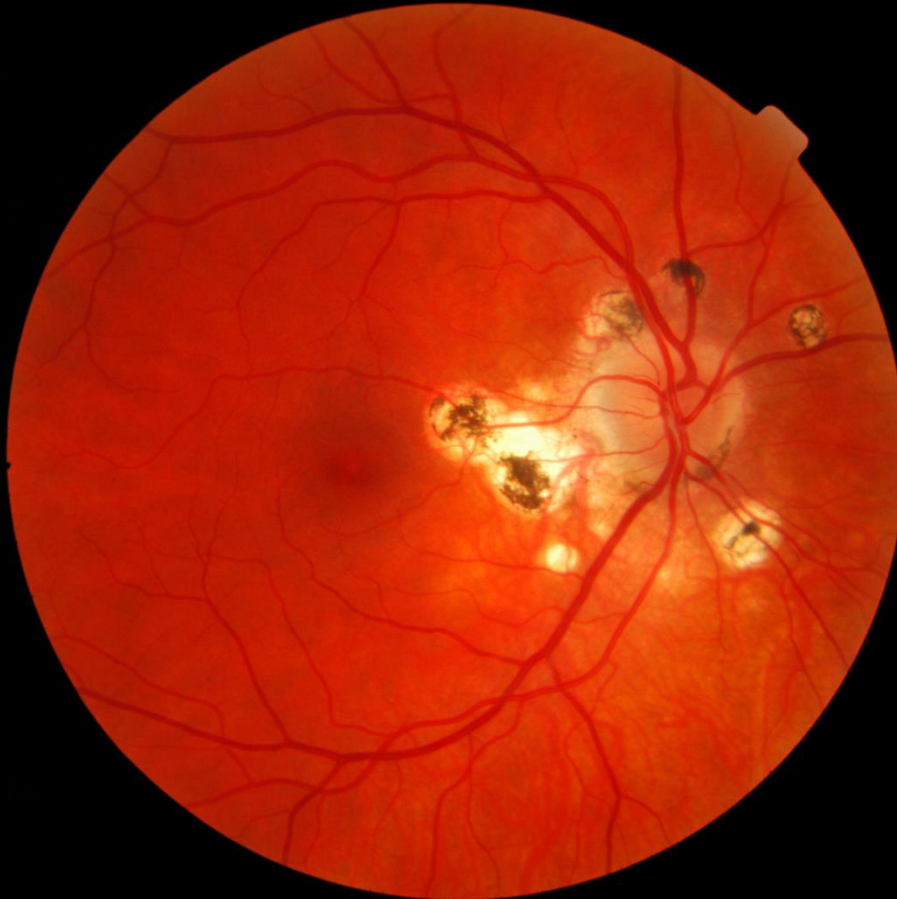Why Grandma Can't See

Why My Grandma Couldn't See
Histoplasmosis

Histoplasma capsulatum



Grandma



Why Grandma Can't See

Why My Grandma Couldn't See Histoplasmosis



Grandma

Treatment:

- None
 - If the central vision is not at risk.
- Laser treatment if central vision is not at risk
- VEGF Injection if central vision is at risk or is involved.

Prevention:

- Wash all vegetables
- Wear a mask when digging or working in the soil
- Wear a mask if working with birds-chickens, pigeons etc.

Why Grandma Can't See

Cataracts

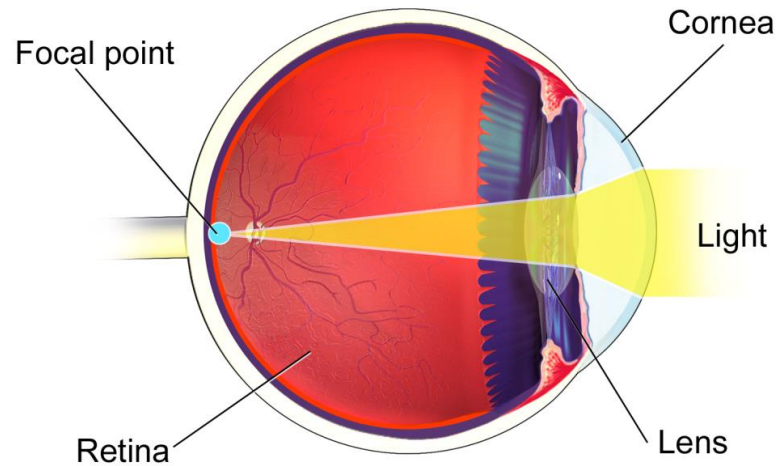
- The incidence is 100%
 - If you live long enough you will have cataracts.
 - Some will not get bad enough to require treatment.
- A cataract is the clouding of the crystalline lens.



Grandma

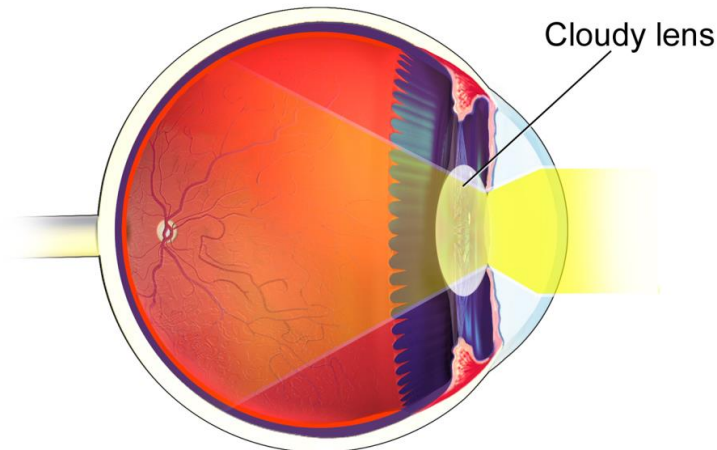
Why Grandma Can't See

Normal Eye



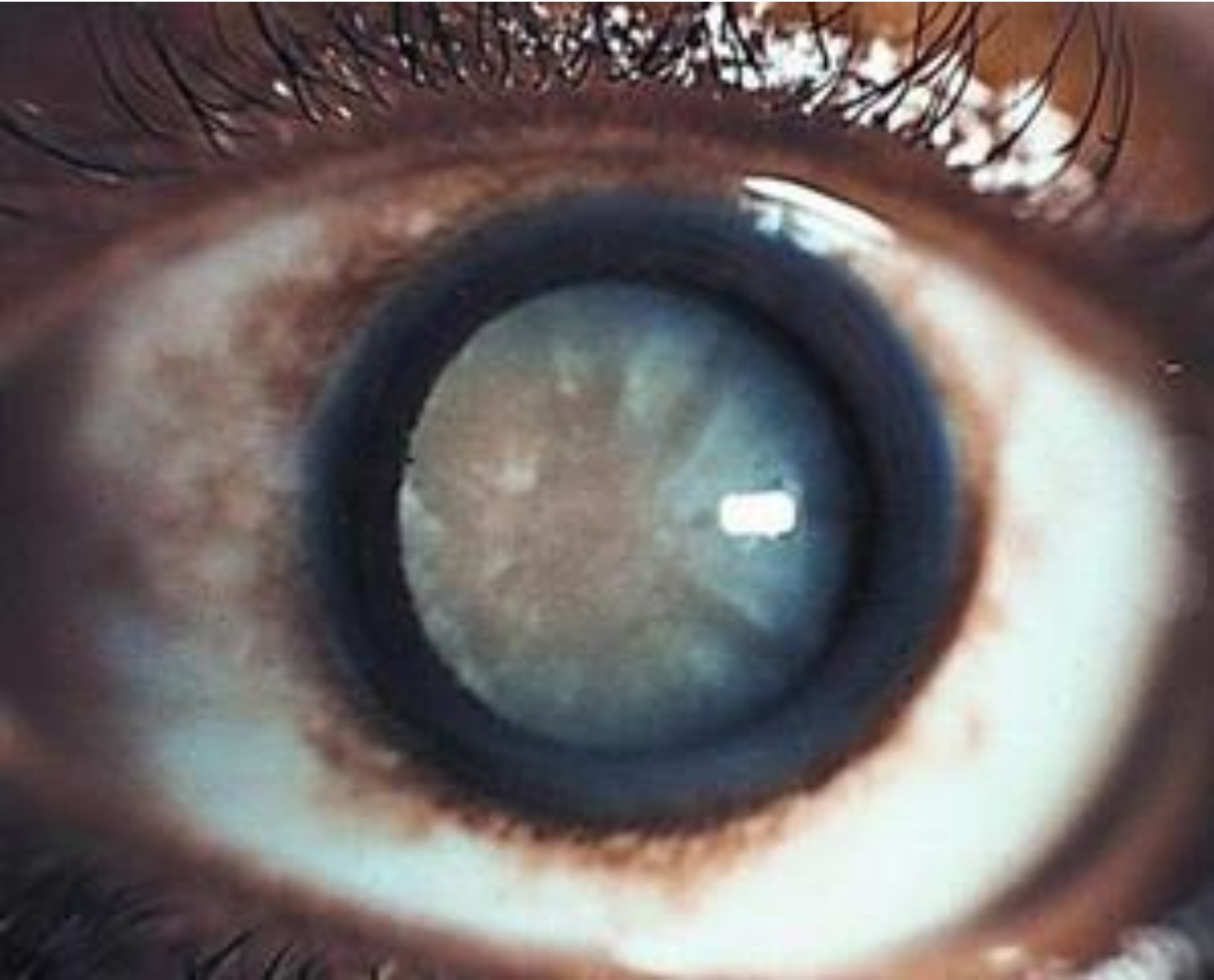Grandma

Eye with Cataract



Cloudy lens, or cataract, causes blurry vision

why Grandma Can't See



Grandma

Why Grandma Can't See

Cataracts

- The incidence is 100%
 - If you live long enough you will have cataracts.
 - Some will not get bad enough to require treatment.
- A cataract is the clouding of the crystalline lens.
- Causes-
 - UV absorption
 - Diet
 - Other medical conditions
 - Genetics



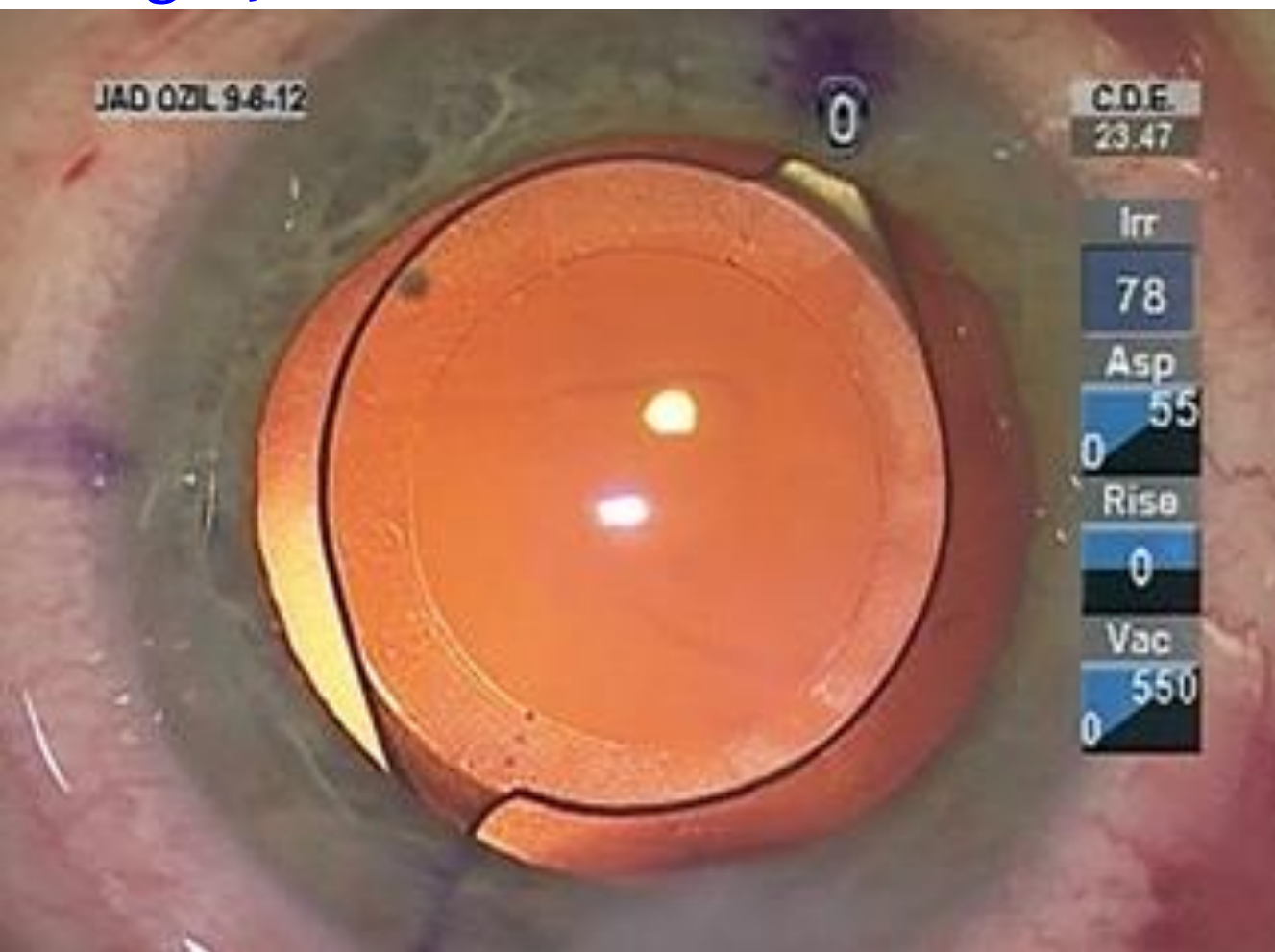
Grandma

Why Grandma Can't See

- Cataracts
- Treatment
 - [Surgery](#)



Grandma



Why Grandma Can't See



Grandma

Cataracts

Treatment

- [Surgery](#)

- Implant-

- Permanent

- Bifocals are available

- Autofocusing Implants are in development

- Astigmatism implants are available

- Prevention

- UV Protection

- Lutein?

- Don't Smoke, quit smoking

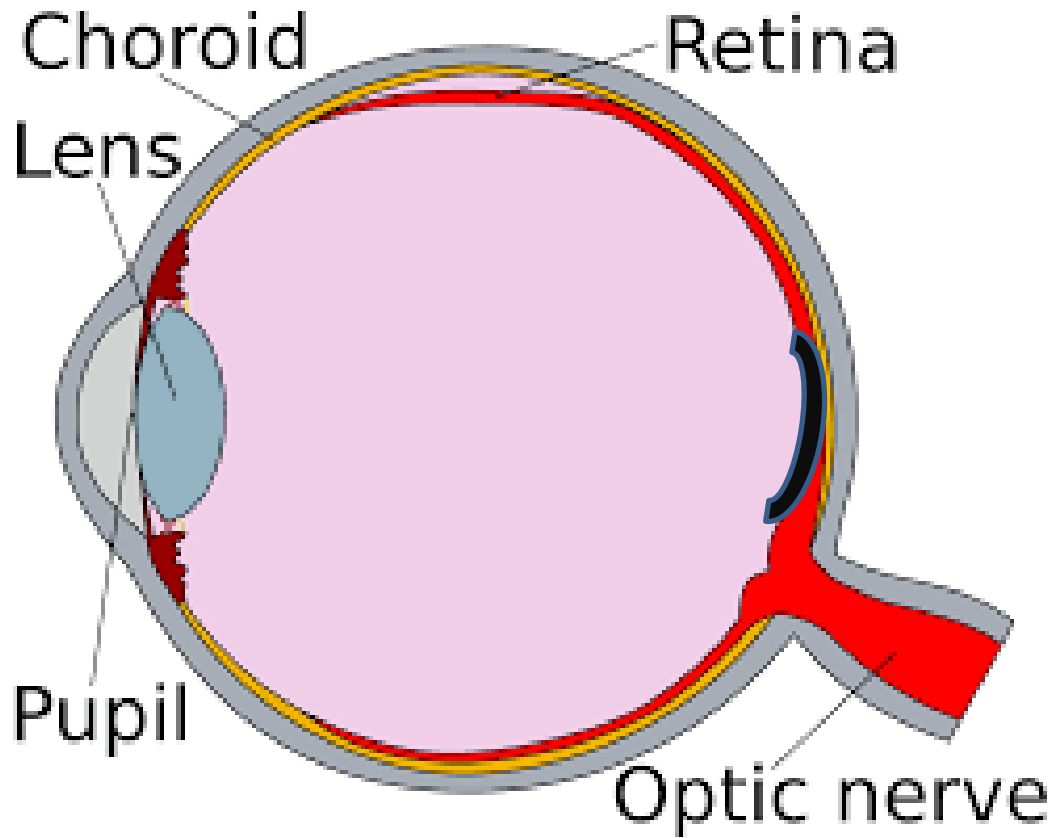
- Healthy Diet

Why Grandma Can't See

Diabetic Retinopathy



Grandma



Why Grandma Can't See

Diabetic Retinopathy

- The number 1 cause of adult blindness
- The longer someone has diabetes the more risk there is of diabetic retinopathy
- The more volatile the glucose levels are the greater risk there is of diabetic retinopathy.
- Cause:
 - High glucose levels cause damage to the tiny blood vessels (capillaries)
 - These can cause microaneurysms
 - Serum leakage
 - Hemorrhages
 - Neovascularization (new, fragile blood vessel growth)



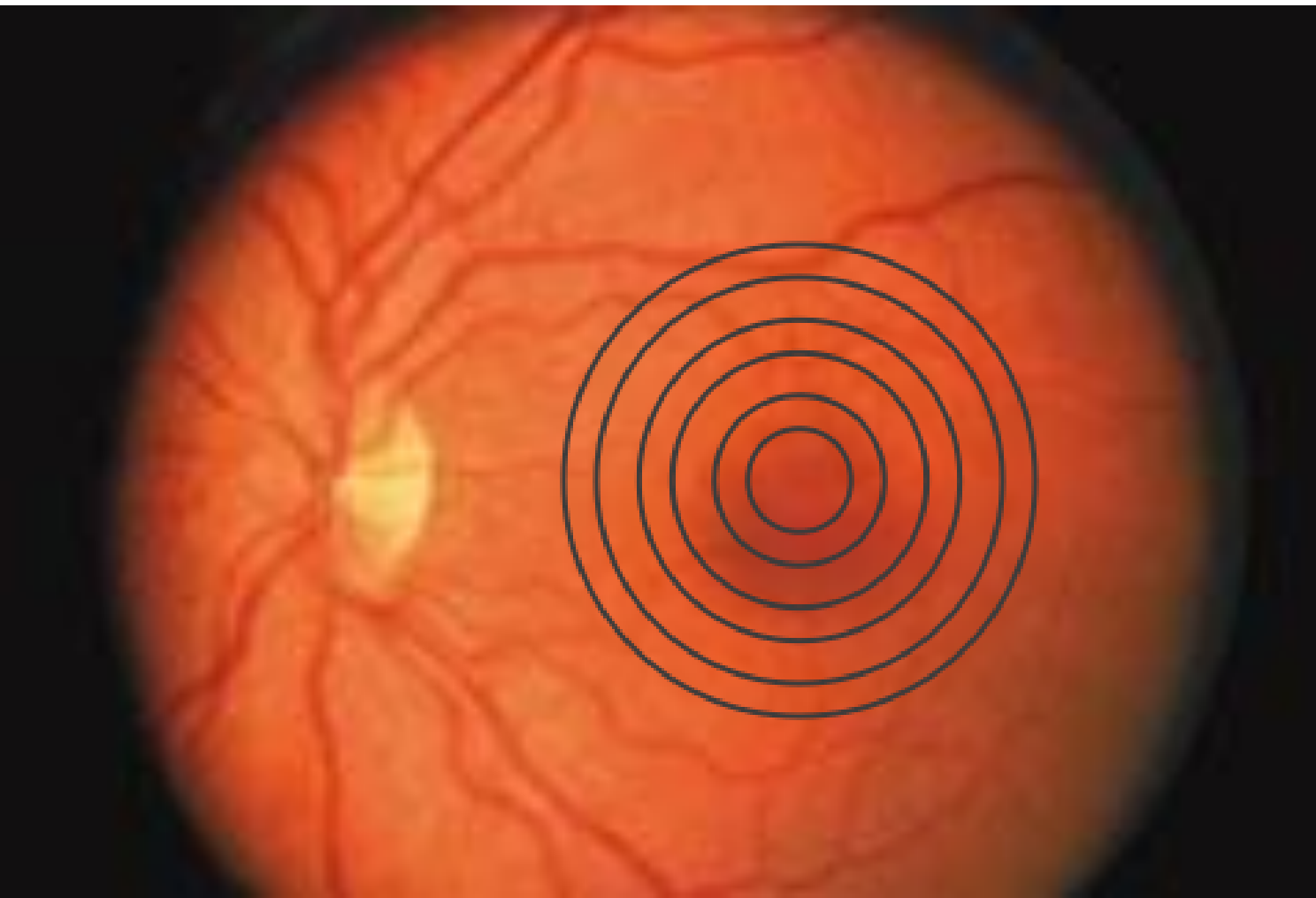Grandma

Why Grandma Can't See

Diabetic Retinopathy



Grandma

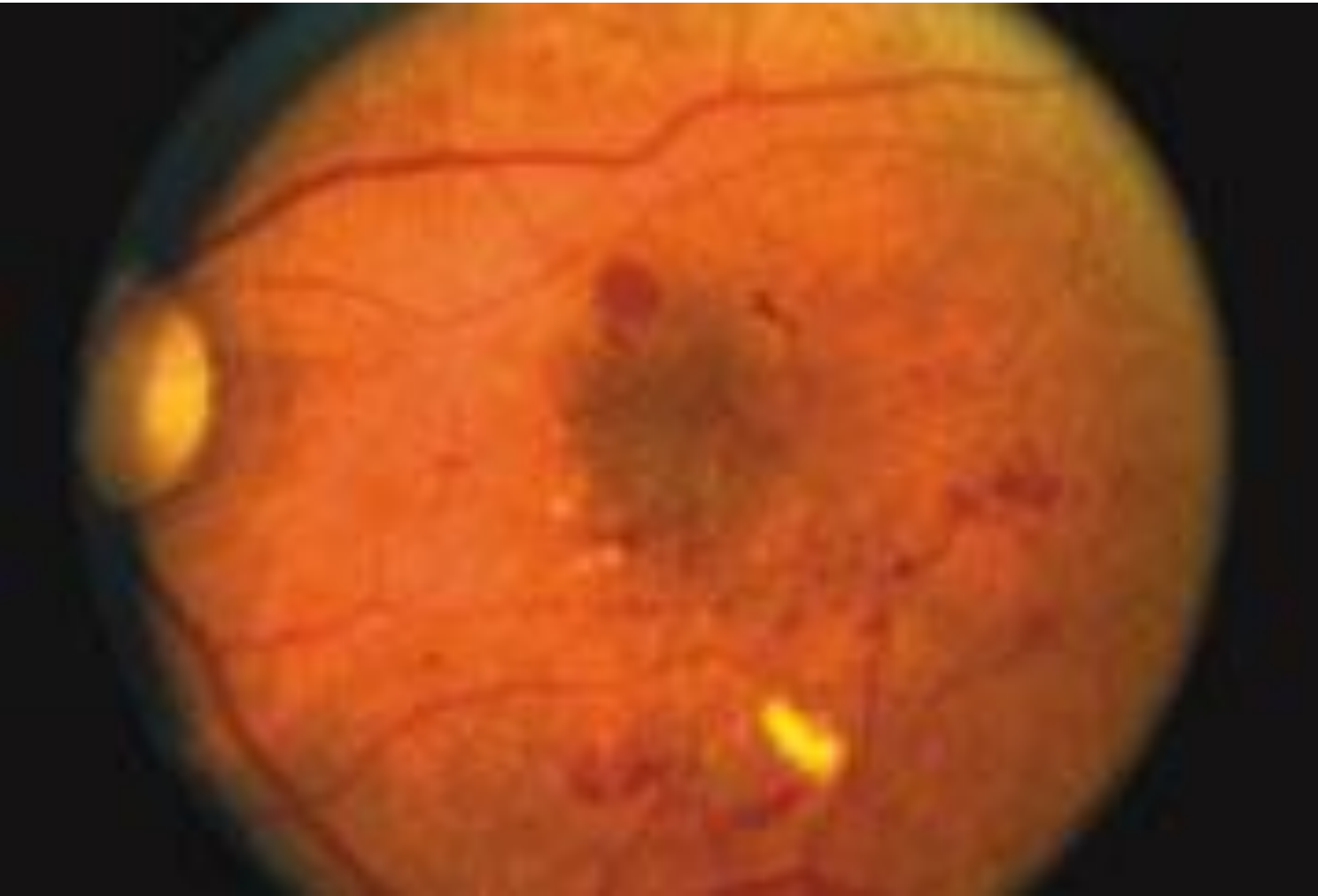

Why Grandma Can't See

Diabetic Retinopathy



Grandma

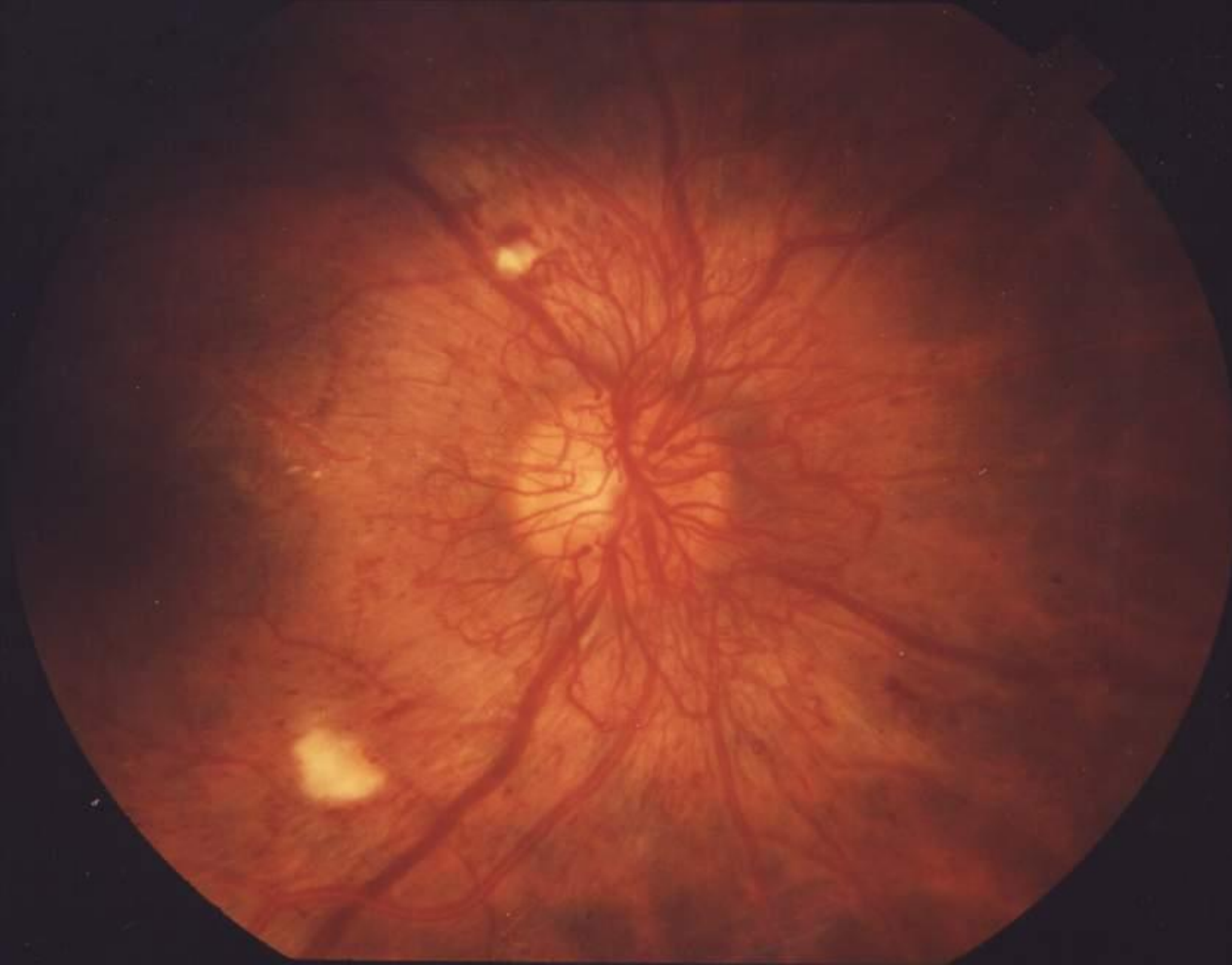

Why Grandma Can't See

Diabetic Retinopathy



Grandma

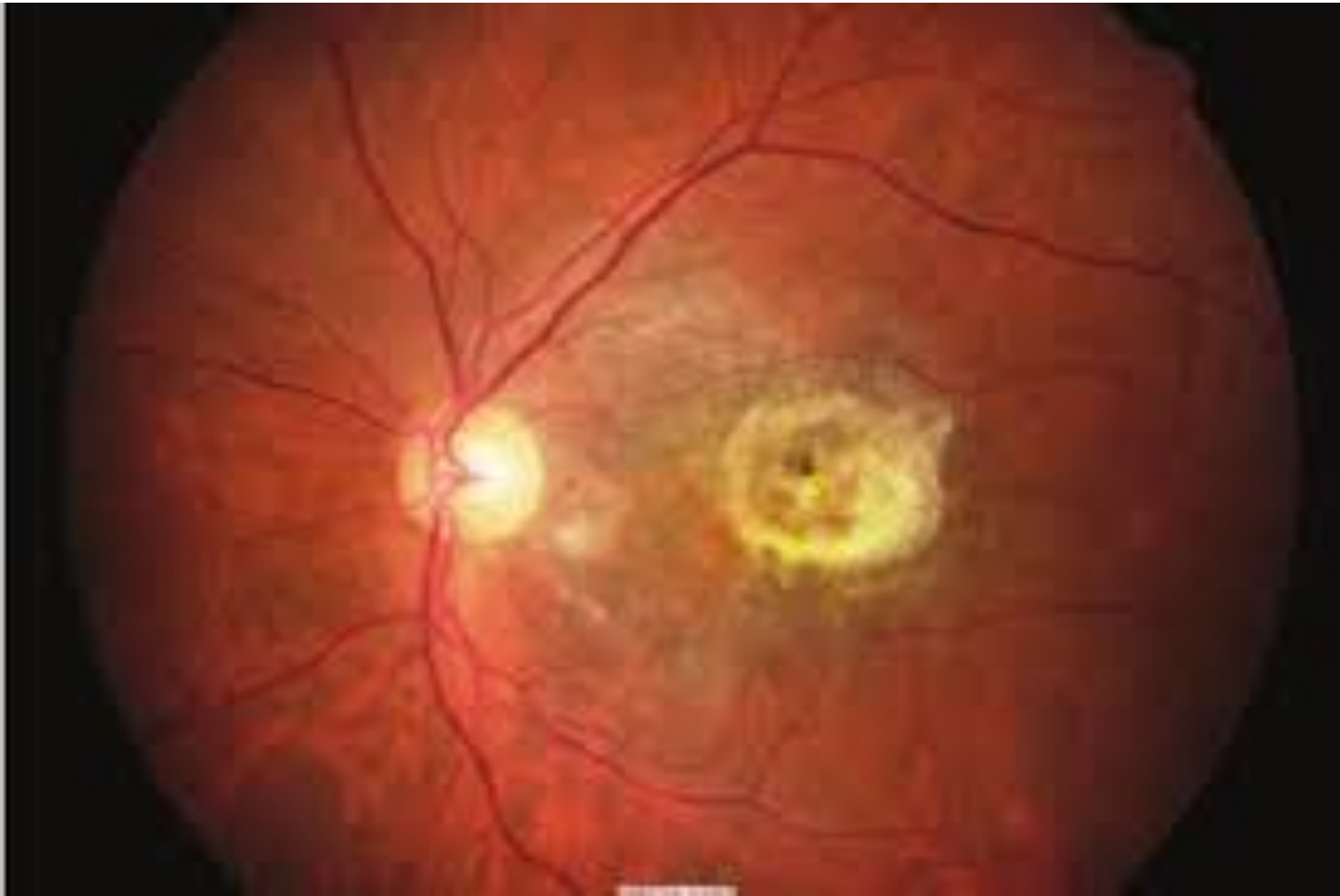

Why Grandma Can't See

Diabetic Retinopathy



Grandma



Why Grandma Can't See

Diabetic Retinopathy

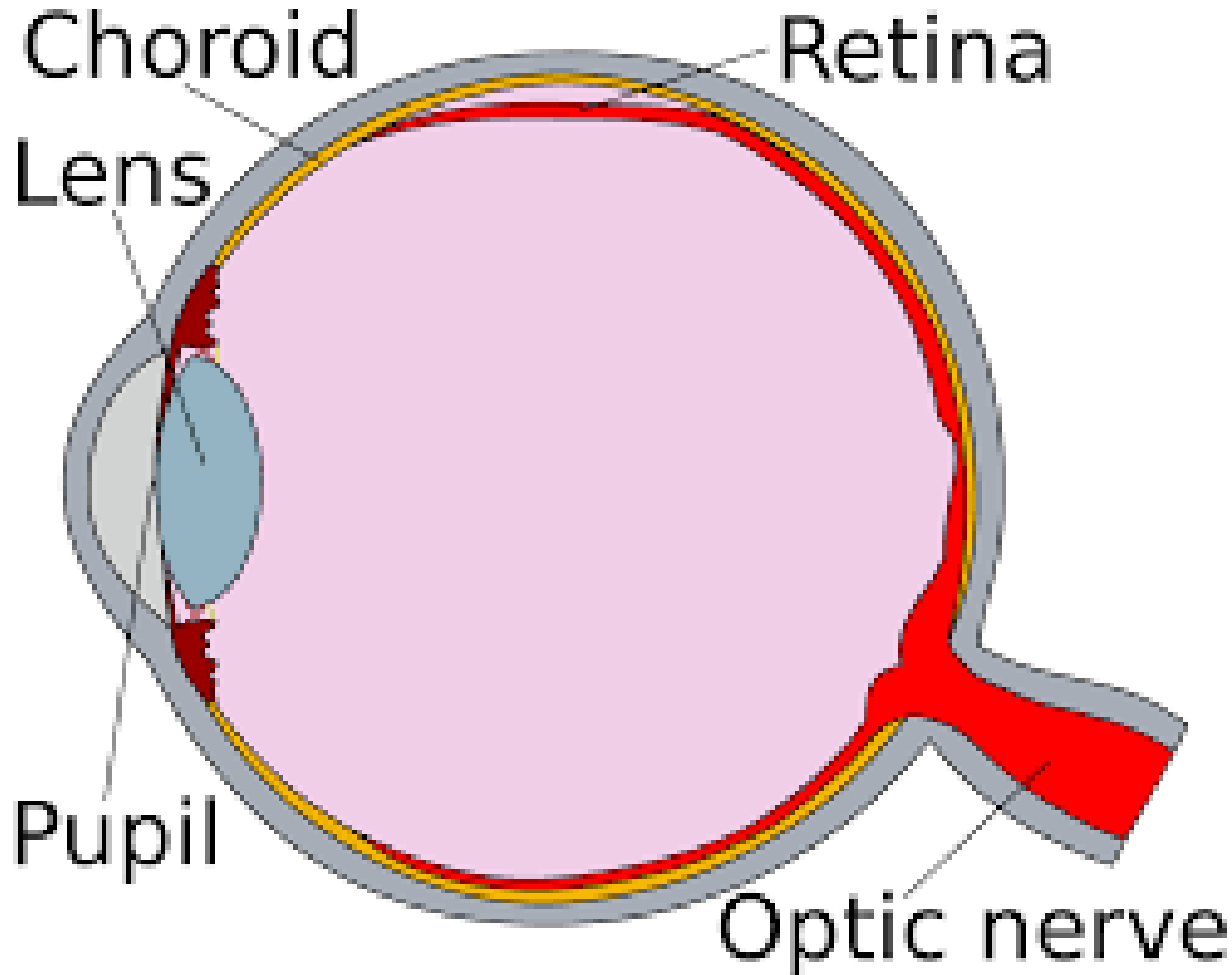
- Treatment
 - Laser
 - VEGF Injection
- Prevention
 - Good glucose control
 - A₁C 6-6.5



Grandma

why Grandma Can't See

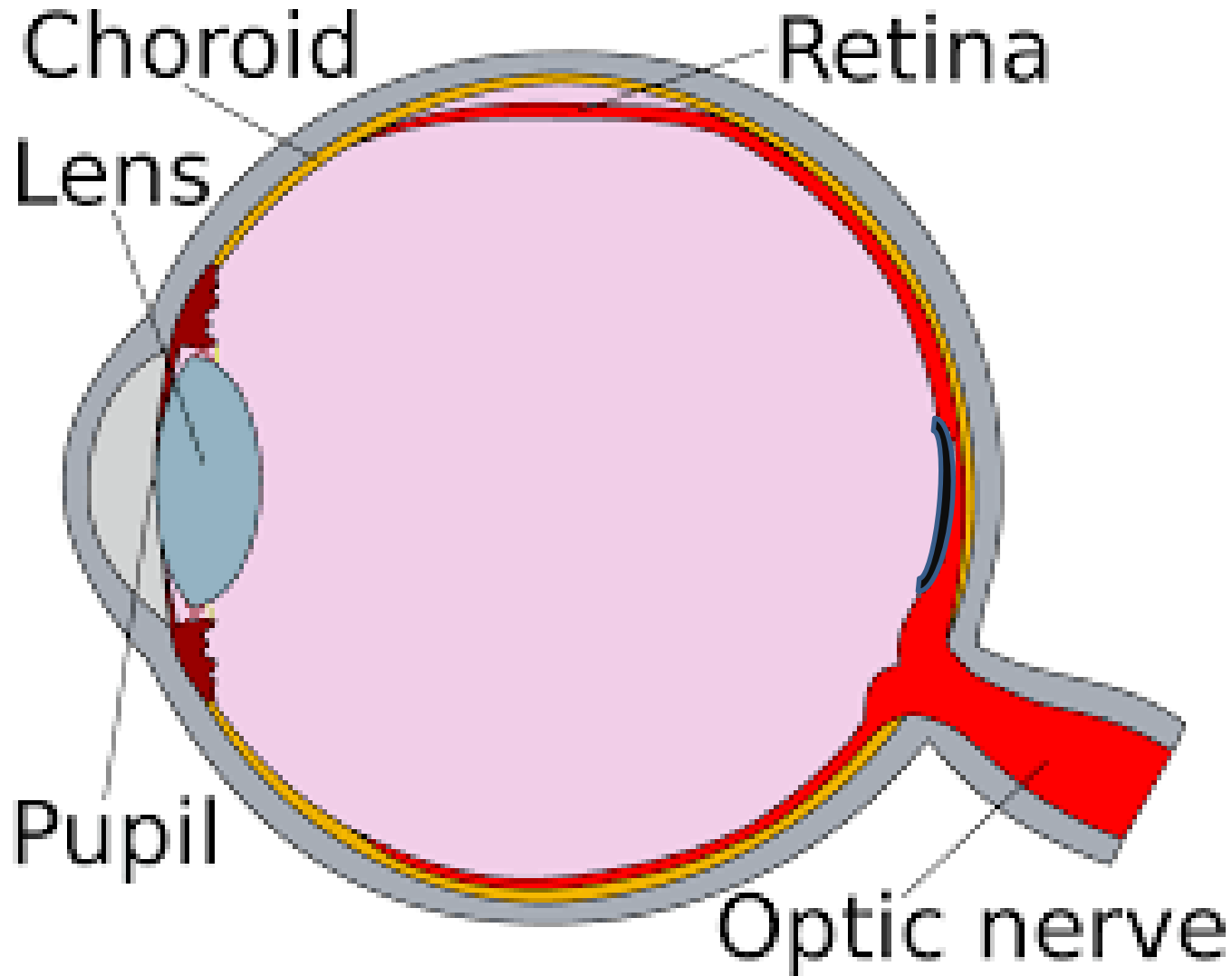
Macular Degeneration



Grandma

why Grandma Can't See

Macular Degeneration



Grandma

Why Grandma Can't See

Macular Degeneration

•Causes

- Genetics
- Smoking
- High fat diet/fried foods
- UV exposure
- More Prevalent among Caucasians

•Two Forms

•Dry

- Accumulation of metabolic debris in the retina.
- Damage to the light sensing layer of the retina in the area of the macula.



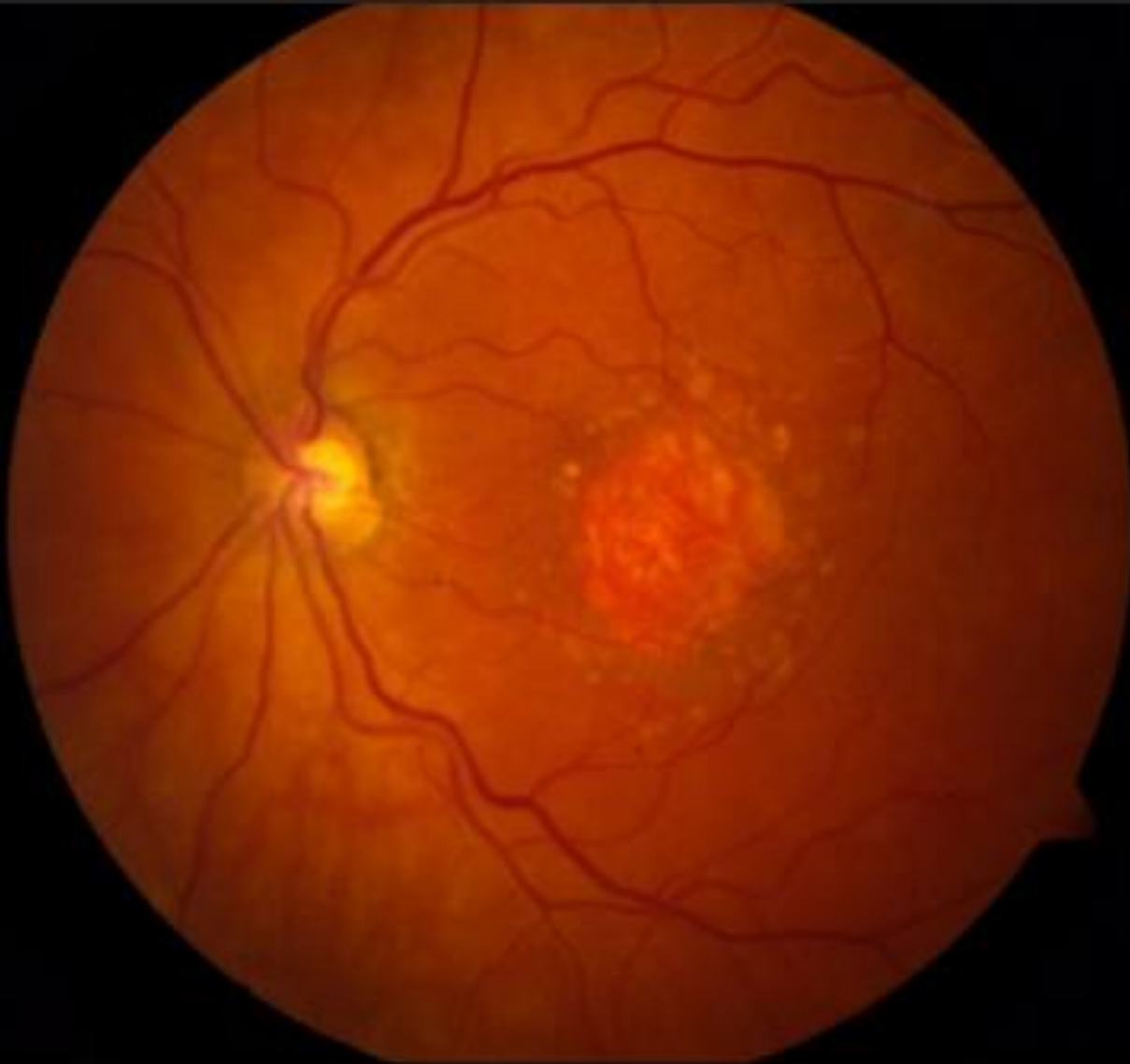
Grandma

Why Grandma Can't See

Macular Degeneration



Grandma



Why Grandma Can't See



Grandma

Macular Degeneration

•Causes

- Genetics
- Smoking
- High fat diet/fried foods
- UV exposure
- More Prevalent among Caucasians

•Two Forms

•Dry

- Accumulation of metabolic debris in the retina.
- Damage to the light sensing layer of the retina in the area of the macula.
- Causes dim areas of the central vision.

Why Grandma Can't See

Macular Degeneration



Grandma



Why Grandma Can't See



Grandma

Macular Degeneration

- Causes
 - Genetics
 - Smoking
 - High fat diet/fried foods
 - UV exposure
 - More Prevalent among Caucasians
- Two Forms
 - Dry
- Accumulation of metabolic debris in the retina.
- Damage to the light sensing layer of the retina in the area of the macula.
- Causes dim areas of the central vision.
- Gradually causes functional blindness

Why Grandma Can't See

- Wet

- Accumulation of metabolic debris causes damage to the layer underneath the retinal: the choroid.
- Vessels from the choroid leak fluid into the macula
- Causes distortion in the central vision.



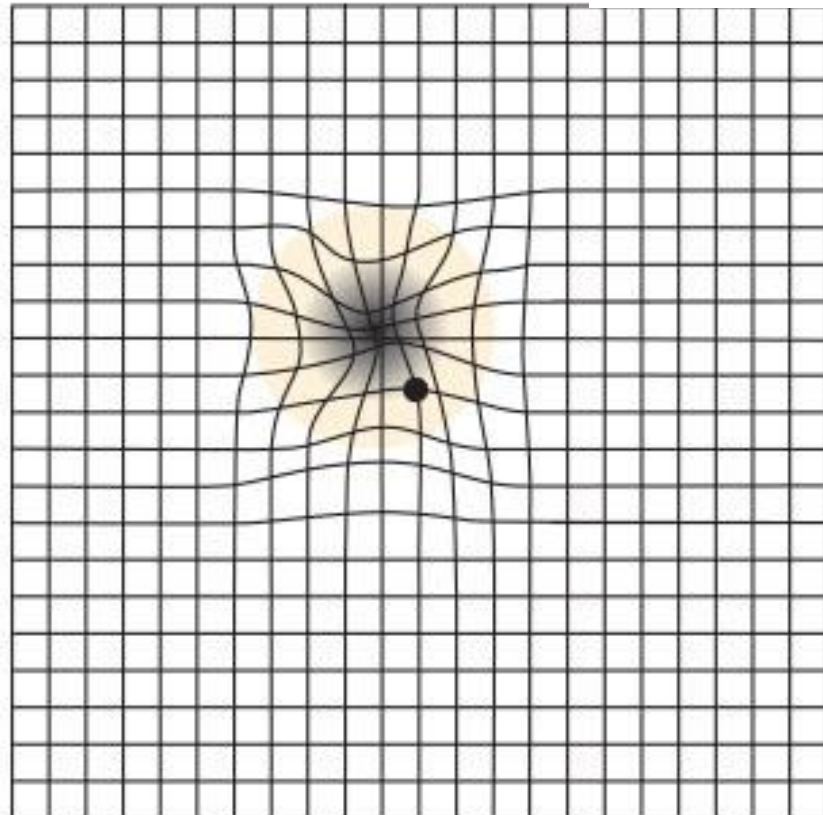
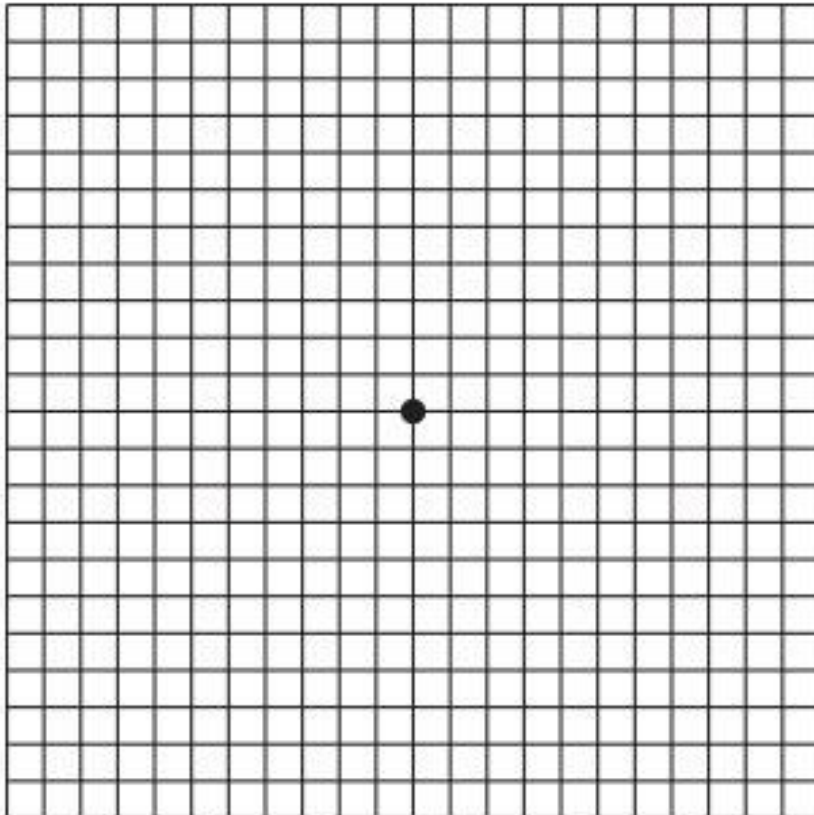
Grandma

why Grandma Can't See

- Causes distortion in the central vision.



Grandma



Why Grandma Can't See

- Wet

- Accumulation of metabolic debris causes damage to the layer underneath the retinal: the choroid.
- Vessels from the choroid leak fluid into the macula
- Causes distortion in the central vision.
- Eventually is leads to hemorrhaging of the blood vessels into the macula



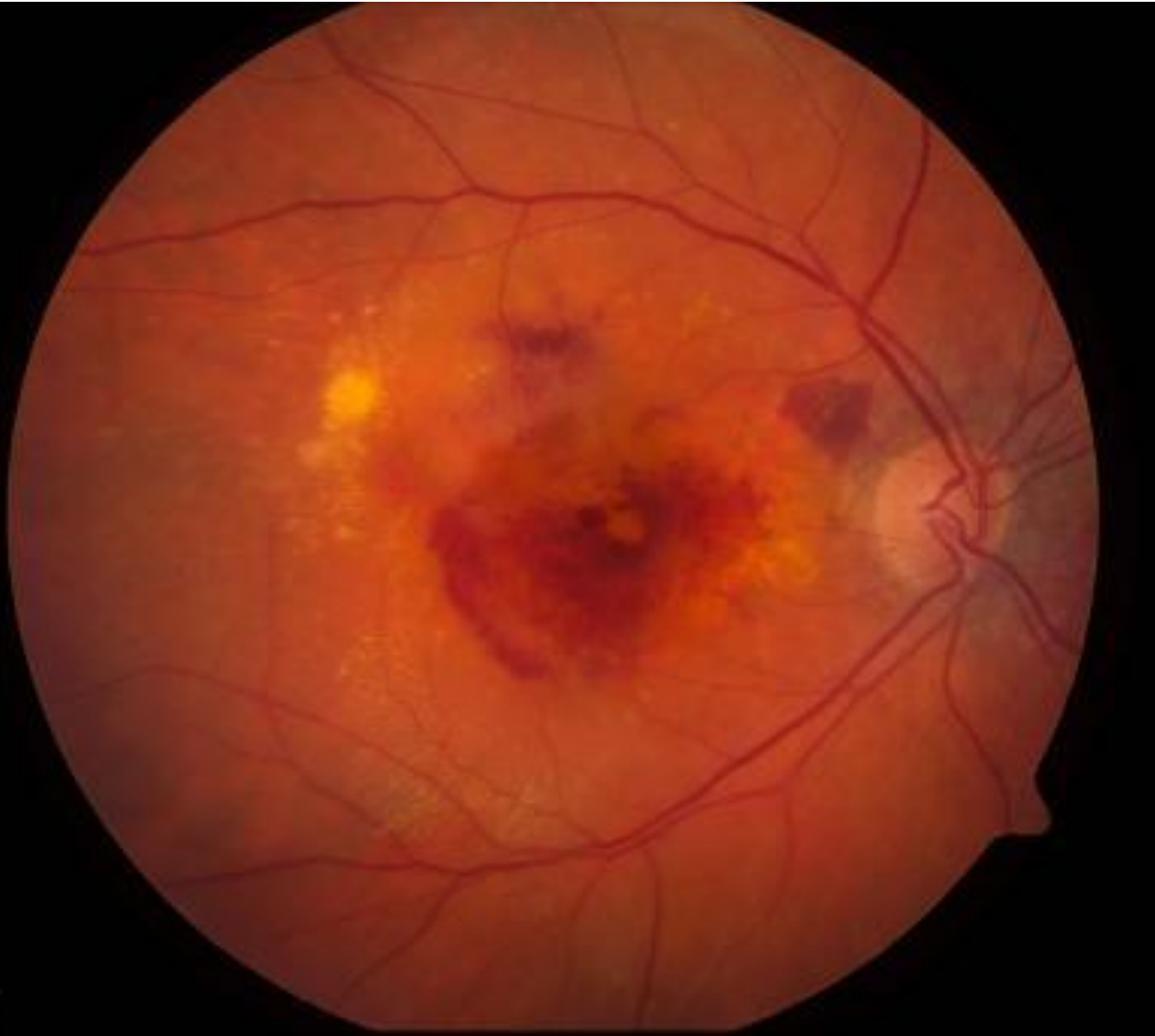Grandma

why Grandma Can't See

- Wet



Grandma



Why Grandma Can't See

- Wet

- Accumulation of metabolic debris causes damage to the layer underneath the retinal: the choroid.
- Vessels from the choroid leak fluid into the macula
- Causes distortion in the central vision.
- Eventually is leads to hemorrhaging of the blood vessels into the macula
- More rapid vision loss than with dry



Grandma

Why Grandma Can't See



Grandma

Macular Degeneration

Treatment:

•Dry-

- Antioxidant Multivitamins-Ocuvite, I Caps, ETC.
 - Caveat-Some people are genetically unable to metabolize the zinc in these preparations. This can cause actual acceleration of the vision loss.
- In FDA trials-gene therapy

•Wet-

- Laser
- VEGF injections

Why Grandma Can't See



Grandma

- Prevention

- Don't Smoke/Stop smoking

- Smoking triples the loss of vision loss in macular degeneration

- High fiber diet

- Exercise

- Good control of Hypertension

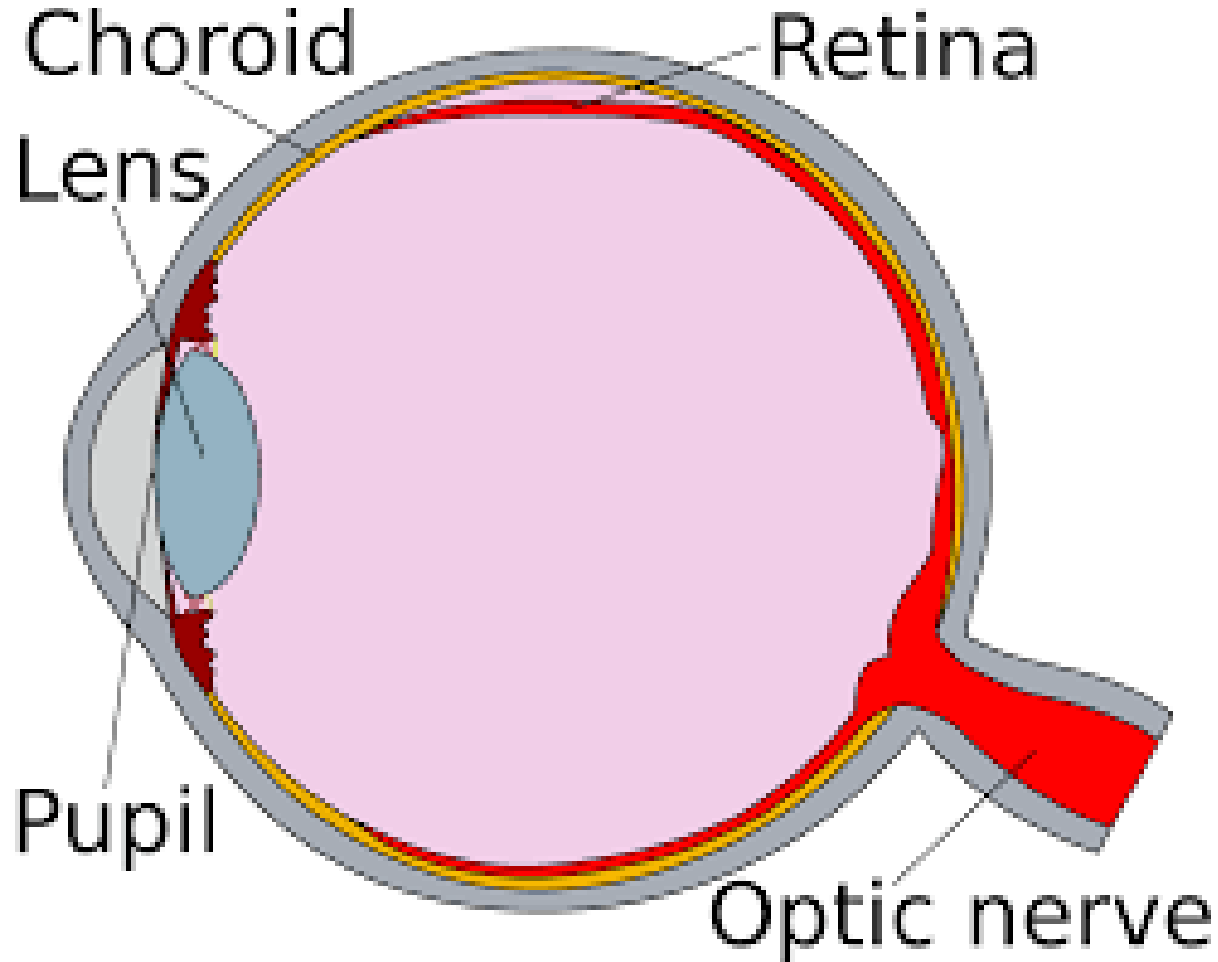
- Healthy "Mediterranean diet"

- Dark green veggies

- Fish

Why Grandma Can't See

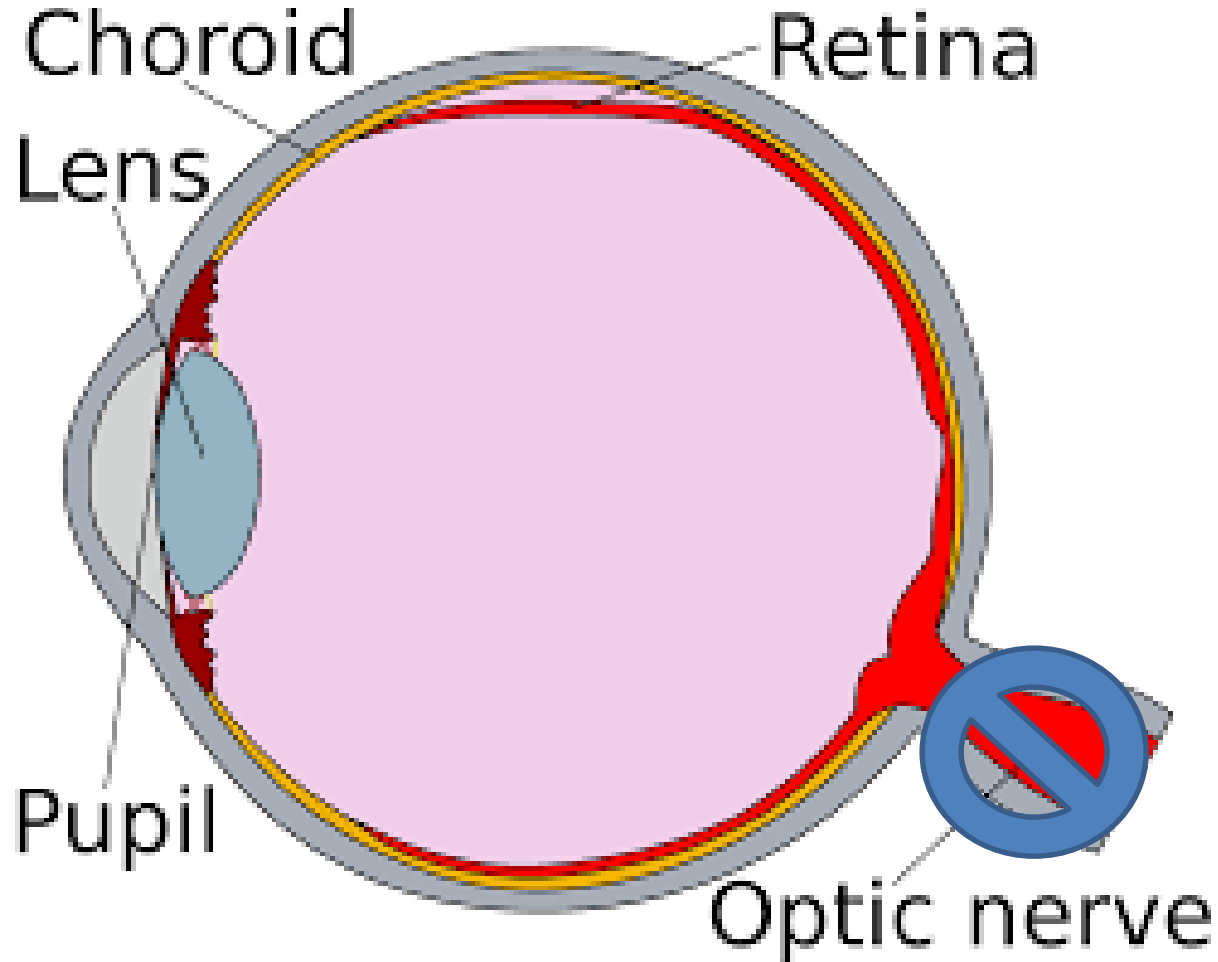
Glaucoma



Grandma

Why Grandma Can't See

Glaucoma



Grandma

Why Grandma Can't See

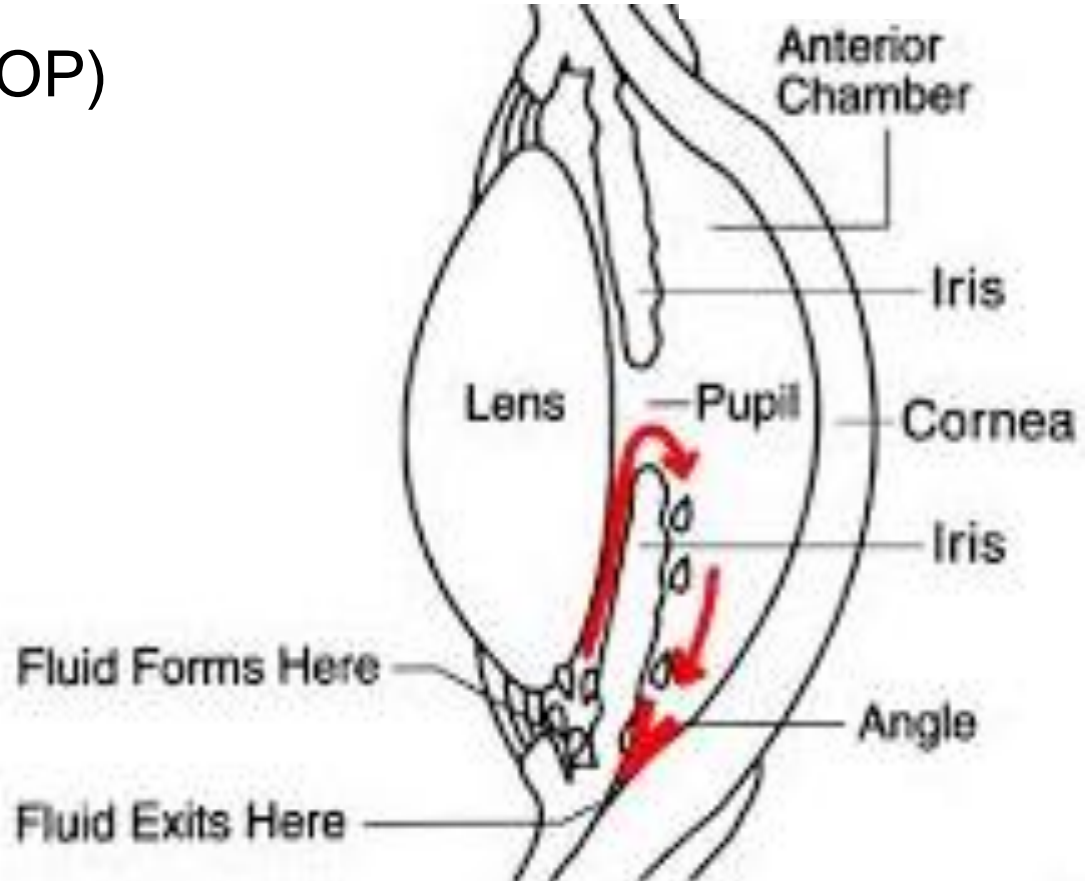
Glaucoma

- Optic Nerve Damage with corresponding visual field loss due to intraocular pressure which is sufficiently higher than the perfusion pressure of the retinal nerve fibers.

- Intraocular Pressure (IOP)



Grandma



Why Grandma Can't See

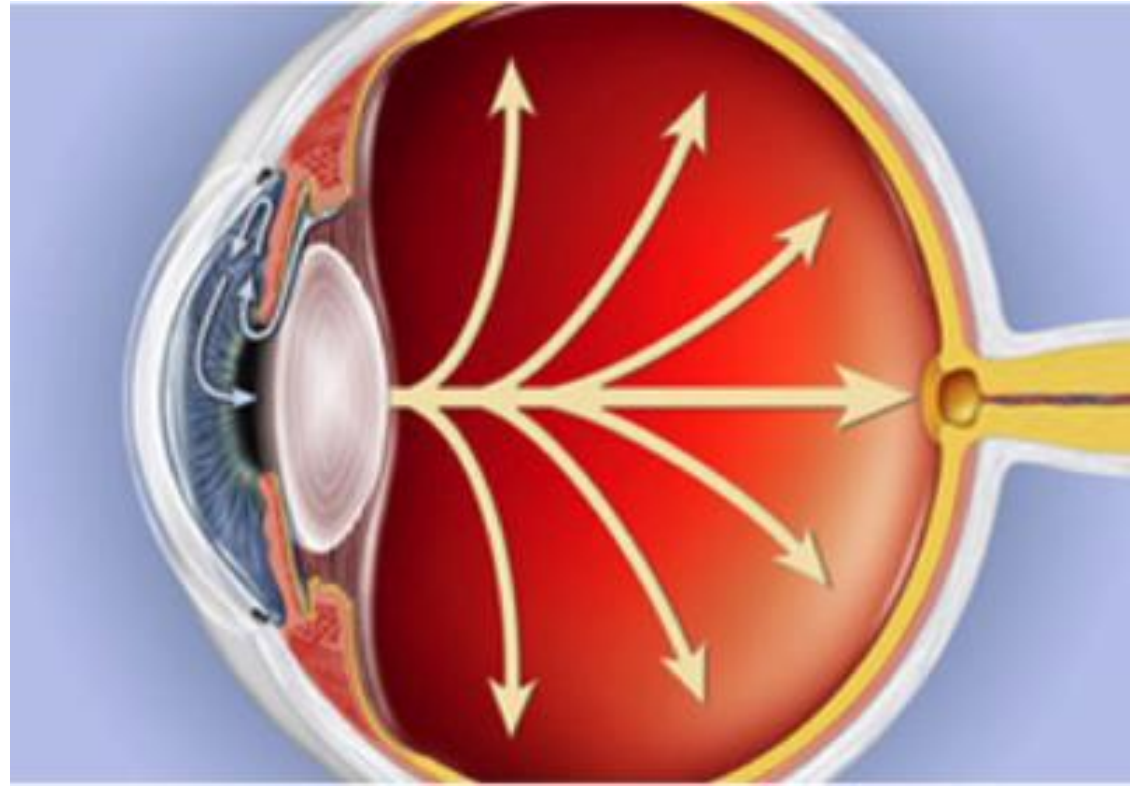
Glaucoma

- Optic Nerve Damage with corresponding visual field loss due to intraocular pressure which is sufficiently higher than the perfusion pressure of the retinal nerve fibers.

- Intraocular Pressure (IOP)
- Optic Nerve Damage



Grandma



Why Grandma Can't See

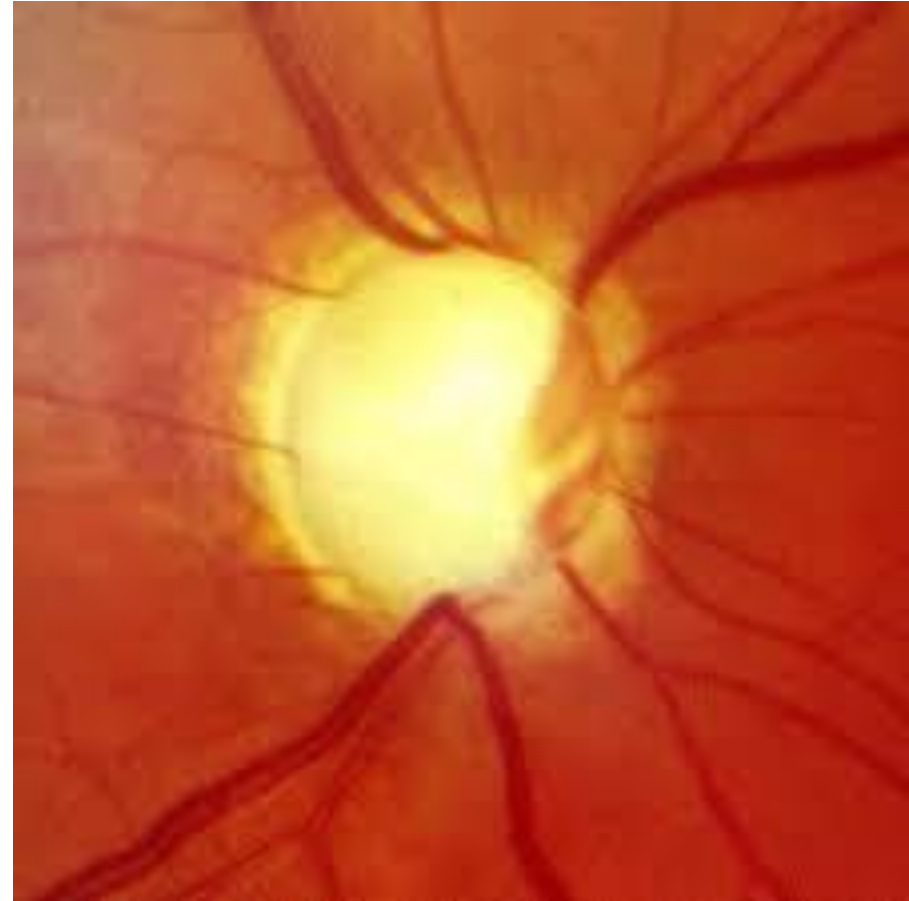
Glaucoma

- Optic Nerve Damage with corresponding visual field loss due to intraocular pressure which is sufficiently higher than the perfusion pressure of the retinal nerve fibers.

- Intraocular Pressure (IOP)
- Optic Nerve Damage



Grandma



Why Grandma Can't See

Glaucoma

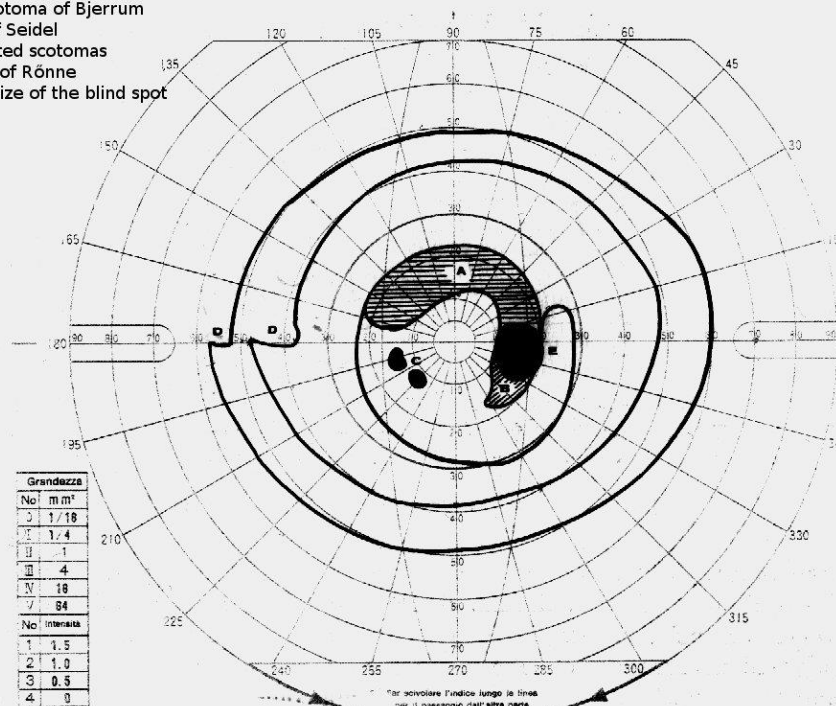
• Optic Nerve Damage with corresponding visual field loss due to intraocular pressure which is sufficiently higher than the perfusion pressure of the retinal nerve fibers.

- Intraocular Pressure (IOP)
- Optic Nerve Damage
- Visual Field Loss



Grandma

- A - arcuate scotoma of Bjerrum
- B - scotoma of Seidel
- C - small isolated scotomas
- D - nasal step of Rönne
- E - increased size of the blind spot



Why Grandma Can't See

Glaucoma

- Optic Nerve Damage with corresponding visual field loss due to intraocular pressure which is sufficiently higher than the perfusion pressure of the retinal nerve fibers.

- Intraocular Pressure (IOP)
- Optic Nerve Damage
- Visual Field Loss



Grandma



Why Grandma Can't See

Glaucoma

•Causes:

- More prominent among those of Africa and Hispanic origin.
- More prevalent with age.
- Genetics

•Prevention:

- None?
- Early Diagnosis is critical and often difficult
 - IOP above 21~24
 - IOP difference of 4 or more
 - IOP with greater than normal daily variation
 - Optic nerve changes
 - Optic nerves that are not mirror images



Grandma

Why Grandma Can't See

Glaucoma

- Treatment

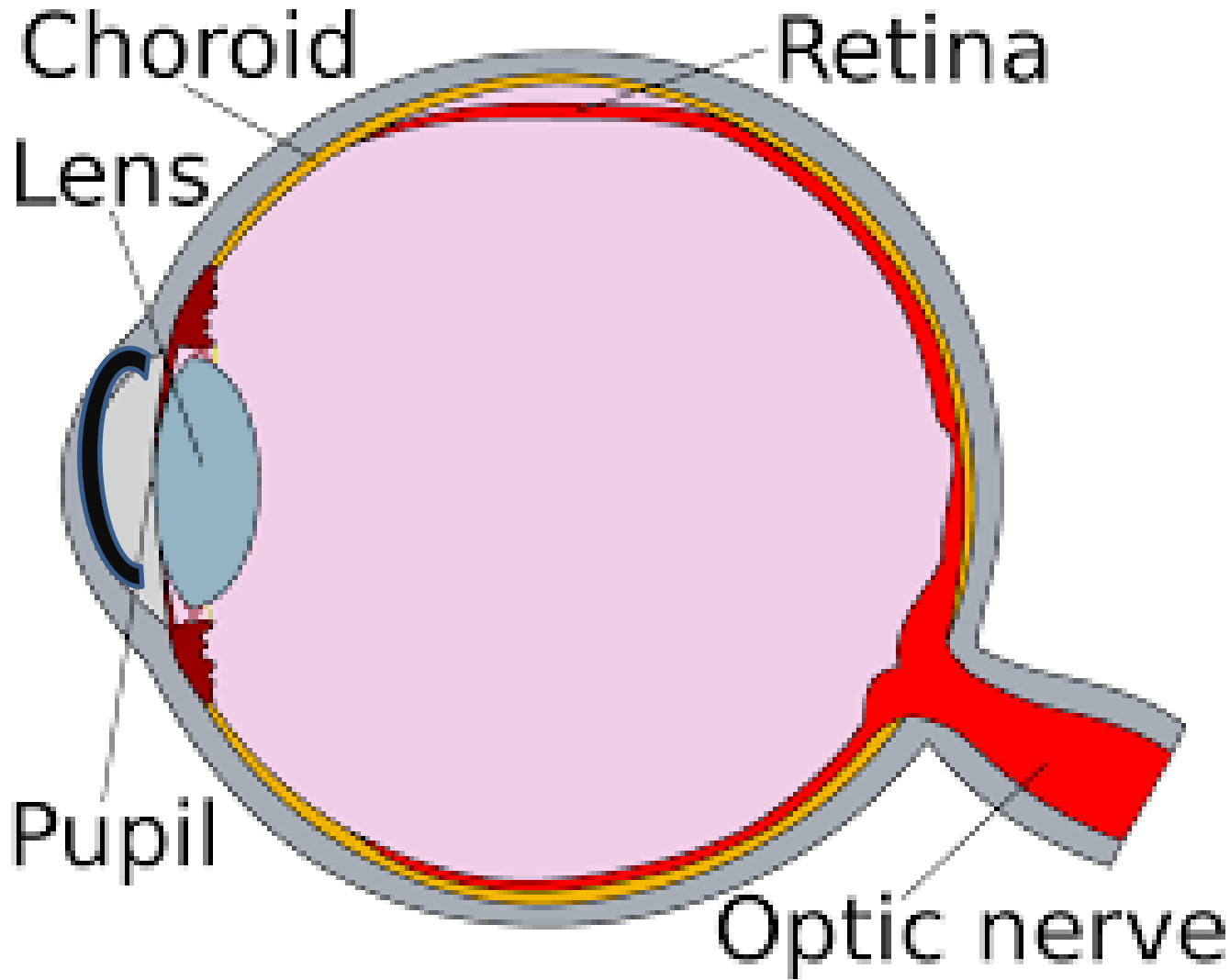
- Pressure Lowering Eye drops
- Laser Surgery (SLT, ALT)
- MIGS-minimally invasive glaucoma surgery
 - Microshunts,
 - Microtubes
- Trabeculectomy



Grandma

Why Grandma Can't See

Fuch's Corneal Dystrophy



Grandma

Why Grandma Can't See

Fuch's Corneal Dystrophy

- More prevalent among women
- Genetic
- Worsens with age
- There is damage to the endothelium
 - Metabolic Debris accumulates in this layer
 - The endothelium controls the fluid level of the cornea
 - When the fluid gets too high the cornea gets cloudy

The Normal Cornea



Grandma

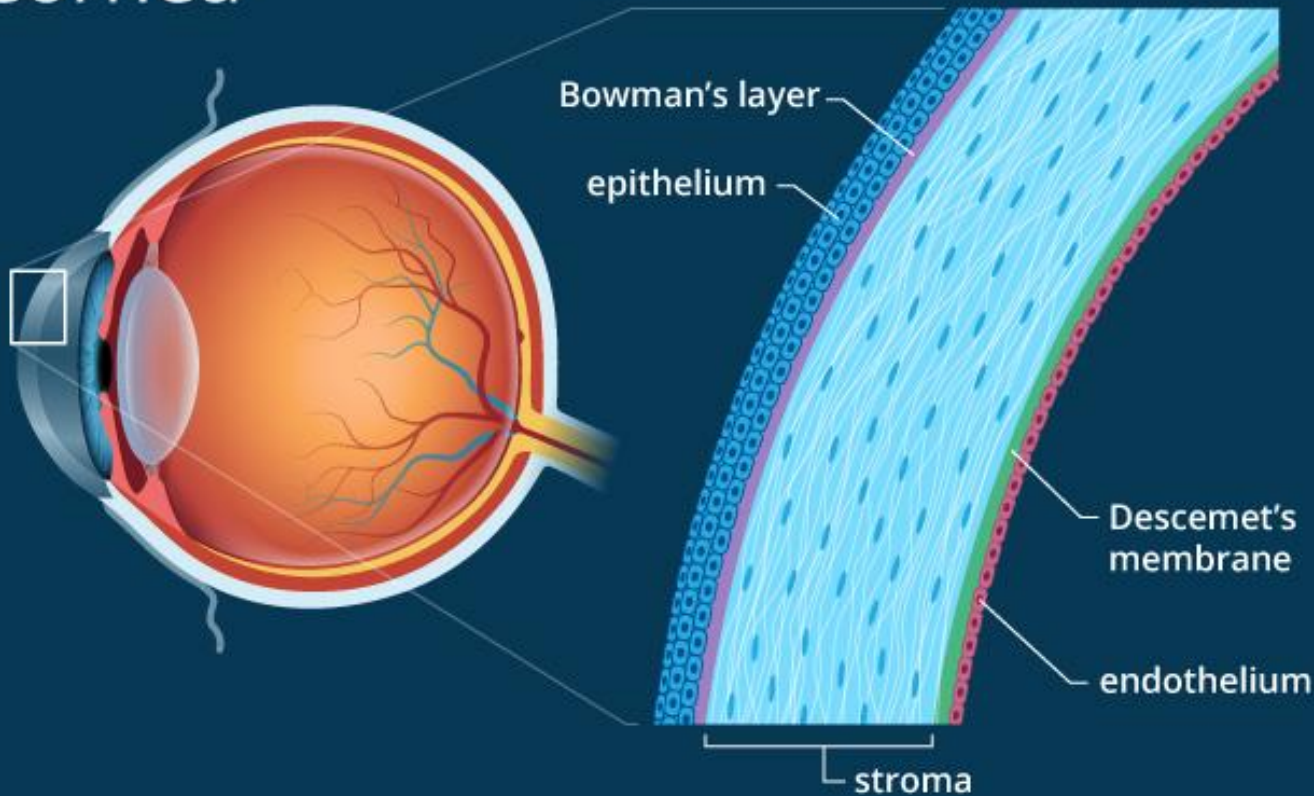
Why Grandma Can't See

Fuch's Corneal Dystrophy



Grandma

Cornea



Why Grandma Can't See

Fuch's Corneal Dystrophy

- More prevalent among women
- Genetic
- Worsens with age
- There is damage to the endothelium
 - Metabolic Debris accumulates in this layer
 - The endothelium controls the fluid level of the cornea
 - When the fluid gets too high the cornea gets cloudy



Grandma

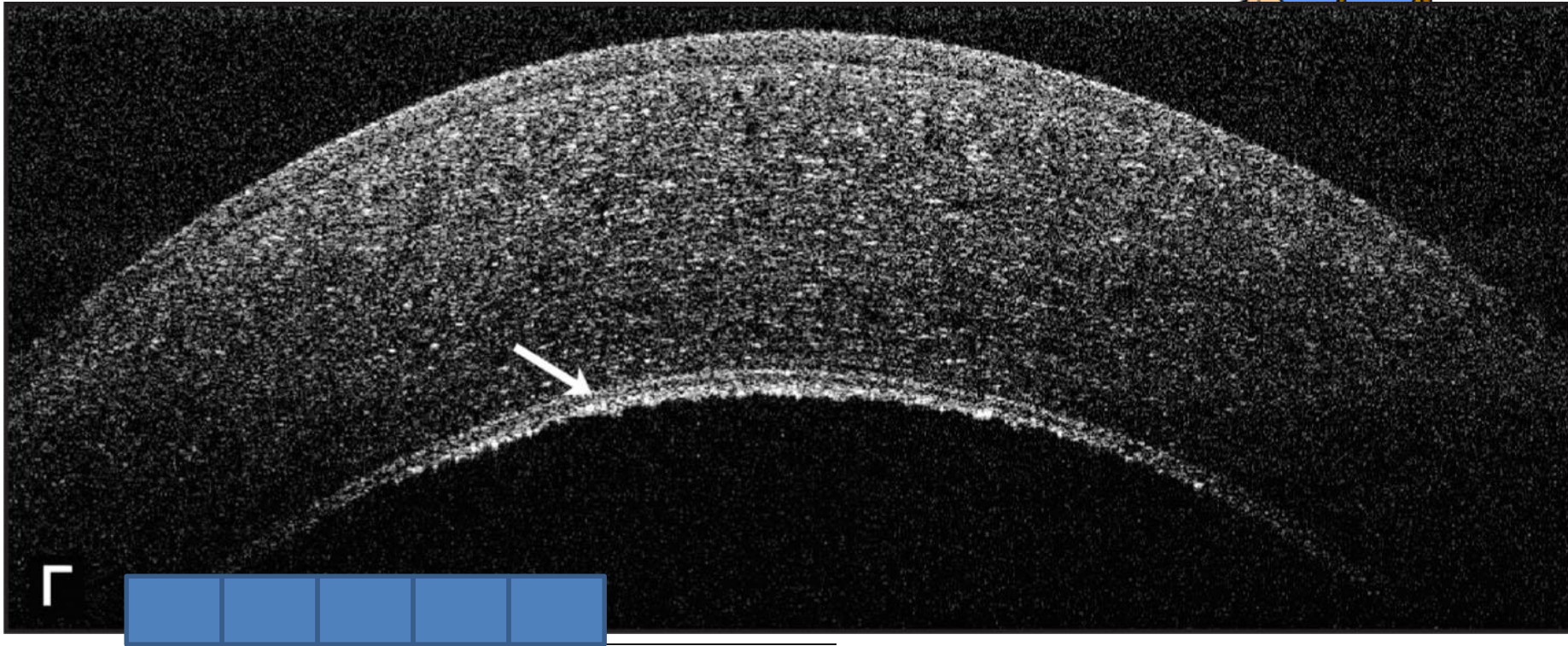
The Normal Cornea

The Normal Endothelium



Why Grandma Can't See

Fuch's Corneal Dystrophy



Why Grandma Can't See

Fuch's Corneal Dystrophy

- More prevalent among women
- Genetic
- Worsens with age
- There is damage to the endothelium
 - Metabolic Debris accumulates in this layer
 - The endothelium controls the fluid level of the cornea
 - When the fluid gets too high the cornea gets cloudy



Grandma

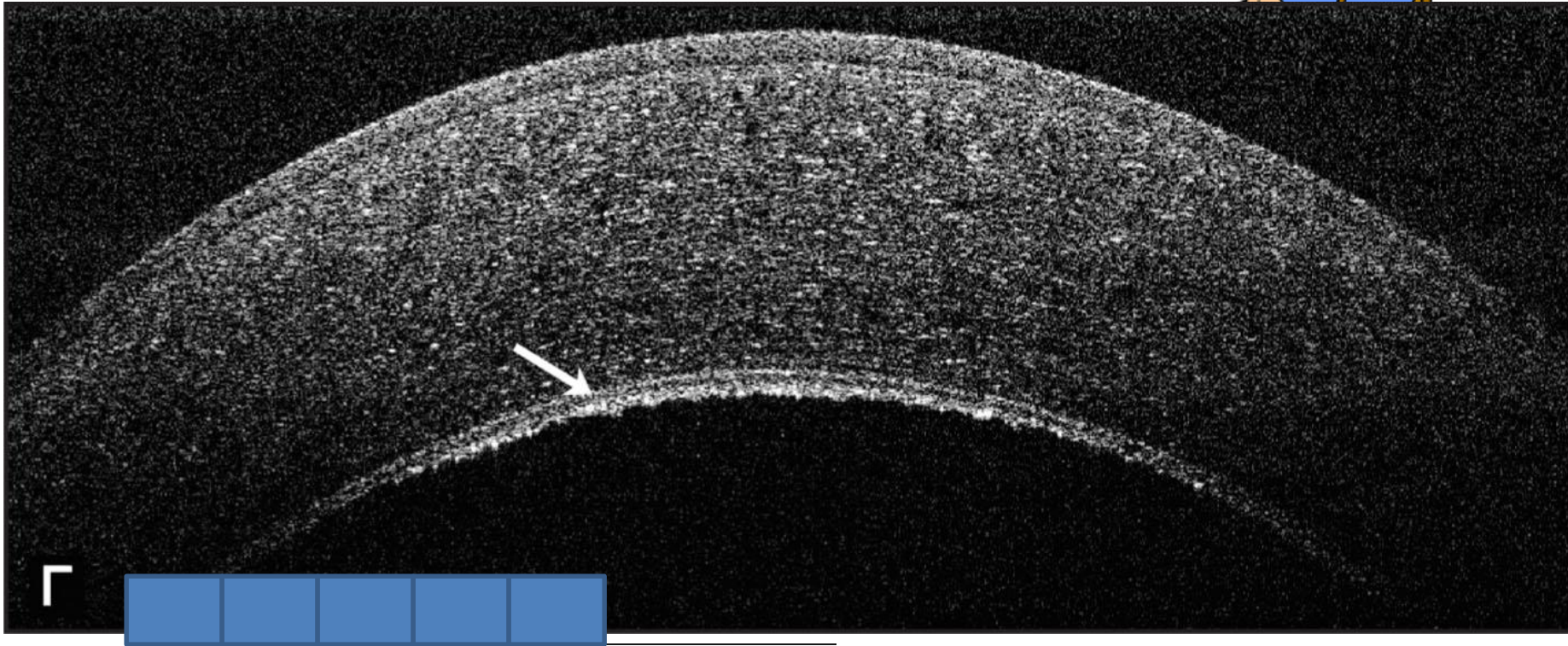
The Normal Cornea

The Normal Endothelium



Why Grandma Can't See

Fuch's Corneal Dystrophy



Why Grandma Can't See

Fuch's Corneal Dystrophy

- More prevalent among women
- Genetic
- Worsens with age
- There is damage to the endothelium
 - Metabolic Debris accumulates in this layer
 - The endothelium controls the fluid level of the cornea
 - When the fluid gets too high the cornea gets cloudy



Grandma

The Normal Cornea

The Normal Endothelium

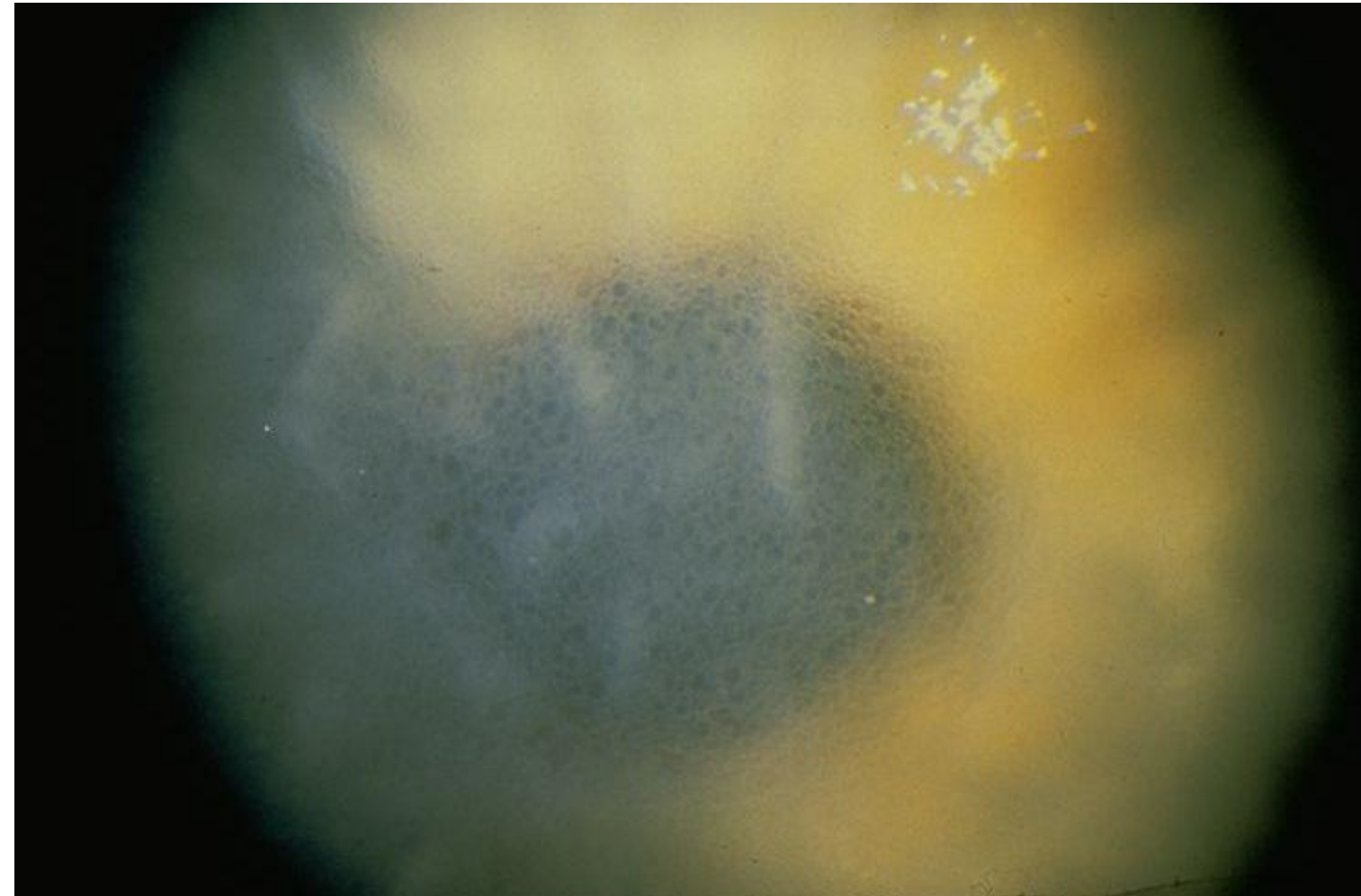


Why Grandma Can't See

Fuch's Corneal Dystrophy



Grandma



Why Grandma Can't See

Fuch's Corneal Dystrophy

- More prevalent among women
- Genetic
- Worsens with age
- There is damage to the endothelium
 - Metabolic Debris accumulates in this layer
 - The endothelium controls the fluid level of the cornea
 - When the fluid gets too high the cornea gets cloudy



Grandma

The Normal Cornea

The Normal Endothelium



Why Grandma Can't See

Fuch's Corneal Dystrophy

Treatment:

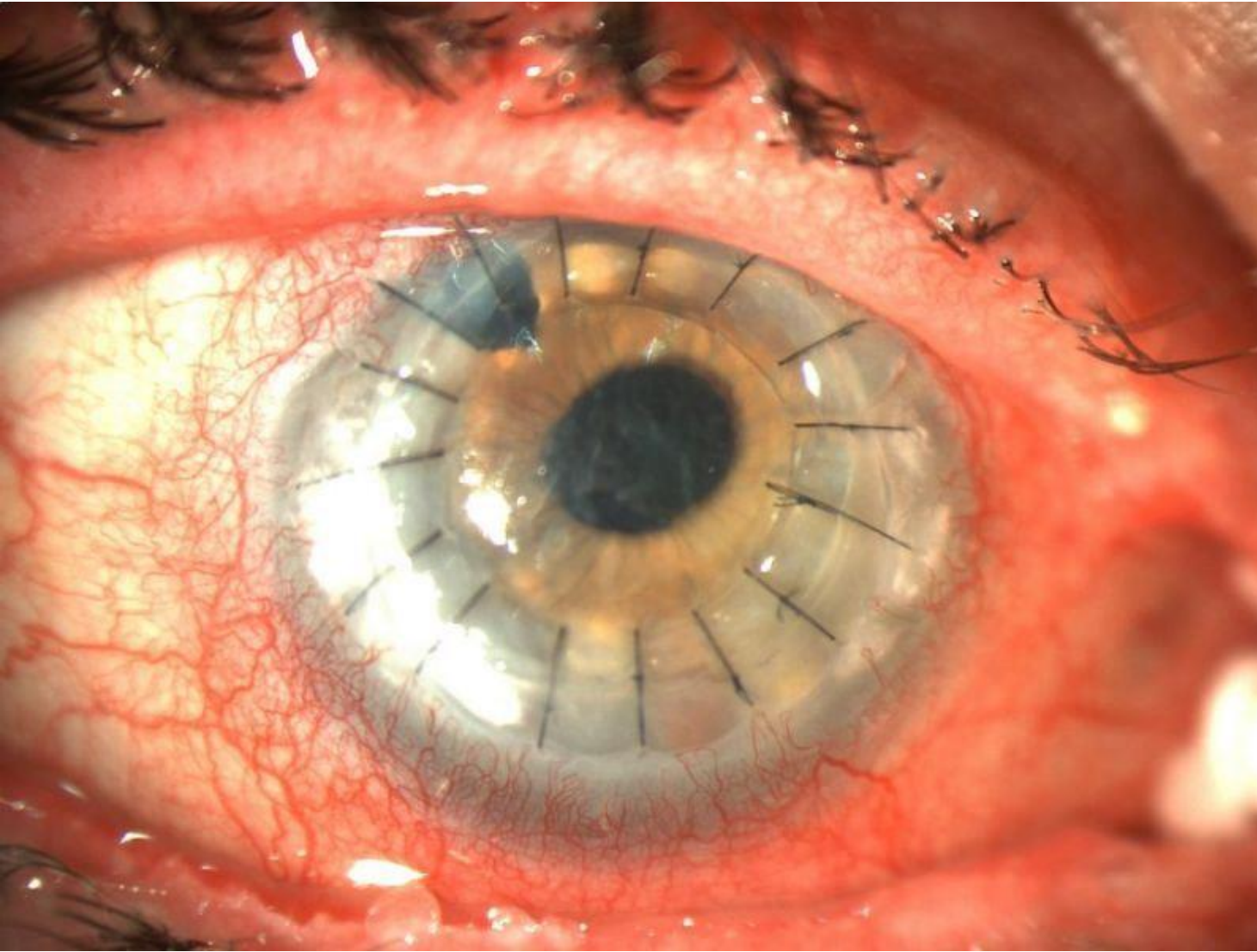
- Hypertonic Saline drops and ointments
- Surgery-Corneal Transplant
 - Lamellar-full thickness



Grandma

Why Grandma Can't See

Fuch's Corneal Dystrophy



Grandma

Why Grandma Can't See

Fuch's Corneal Dystrophy

Treatment:

- Hypertonic Saline drops and ointments
- Surgery-Corneal Transplant
 - Lamellar-full thickness
 - Posterior Only
 - DSEK
 - DMEK

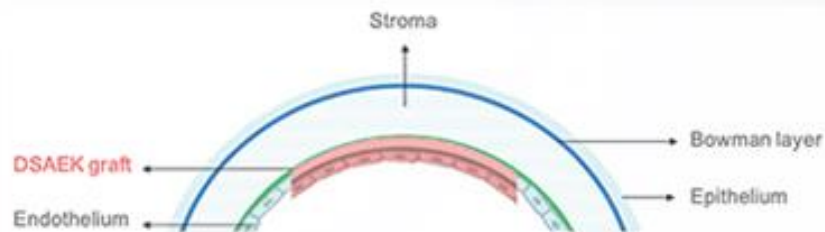


Grandma

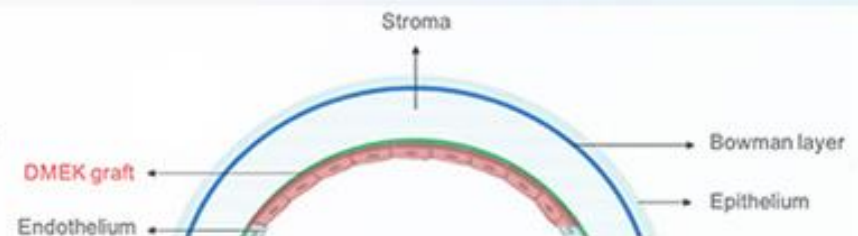
Prevention

- None

DSAEK



DMEK



Why Grandma Can't See

Dr. Jay Pass's presentation on Eye Health
has been edited for PDF friendliness by Website Administrator.
Apologies to Dr. Pass for any inadvertent mistakes.



Grandma

